

Radiographic Assessment of Periodontal Ligament and Root Pulp Visibility in Lower Third Molars as a Tool for Chronological Age Estimation

Mahwish Sami¹, Sarwat Memon^{2*}, Fizza Saher³, Qudsia Hassan⁴

ABSTRACT

OBJECTIVE: To assess chronological age by radiographic assessment of root pulp visibility and periodontal ligament visibility of lower third molar teeth through stage classification in a subset of the Pakistani population.

METHODOLOGY: A cross-sectional study was conducted using digital orthopantomograms (OPGs) of 260 lower third molar teeth aged 18-40 years, using a non-probability consecutive sampling technique from the Department of Orthodontics, Ziauddin University Hospital and Karachi X-rays Center taken between the year 2020 to 2022. The OPGs were studied using Clear Canvas software. The OPGs with good contrast, good quality image and good morphology with complete root formation were included; OPGs with missing required teeth, teeth with fillings, inflammation or anomaly were excluded.

RESULTS: A significant association was seen between stages of RPV and PLV with chronological ages. For both sexes, the mean ages for RPV at stages 0, stage 1 and stage 2 were found to be 24.26 years, 29.71 years and 32 years, respectively and mean ages for PLV at stages 0, stage 1 and stage 2 were found to be 24.16 years, 28.31 years and 32.44 years respectively.

CONCLUSION: The individuals found at stages 0 and 1 for radiographic RPV were at least 18 years of age, and for stage 2, individuals were 28 years and above. For radiographic PLV, the minimum age for stage 0 and stage 1 were at least 18 years, and for stage 2, the individuals were at least 20. Hence, RPV and PLV methods can be used to estimate age.

KEYWORDS: Periodontal ligament, dental radiographs, dental pulp, age estimation, orthopantomogram, root pulp, radiography

INTRODUCTION

Teeth are regarded as a highly mineralized hard tissue due to their composition of enamel, dentin and cementum¹. Due to these features, teeth resist thermal, mechanical, and chemical stimuli and are least affected by changes in environment, genetics, hormones, and nutrition. Hence, teeth are categorized as essential parameters for age estimation².

SDD (Secondary dentin deposition) in a tooth starts when the tooth becomes entirely functional in the mouth and continues throughout life. SDD gradually narrows the pulp canals, increasing the over-lying tissues' radio-opacity in obscured pulp on a panoramic radiograph. The periodontal ligament also thins out as

an individual ages, increasing the over-lying tissues' radio-opacity and an obliteration of the ligament space on a panoramic radiograph can be seen^{1,2}.

Considering radiographic changes in the root pulp visibility (RPV) and the periodontal ligament visibility (PLV) with increasing age of an individual, Olze et al. proposed two criteria, which were based on studying RPV and PLV radiographically of lower third molar teeth for estimation of chronological age, with completed root formation and apical closure^{3,4}. These methods have been confirmed as reliable age markers for 18 and 21-year thresholds for different populations⁵. Therefore, this study aims to provide a simple, supplementary method for estimating age using dental radiographs (OPG) and to create a data bank for our subset of the Karachi population.

METHODOLOGY

A cross-sectional study assessed chronological age based on the radiographic RPV and PLV in lower third molar teeth in a subset of the Pakistani population.

This study comprised OPGs of males and females taken between 2020 and 2022, the patient's date of birth, the date when the radiograph was taken, and the sex was recorded. However, the individuals' names and surnames were not recorded while examining and analyzing the OPGs. The digital OPGs were examined and analyzed on a computer screen

¹Department of Oral Biology, Ziauddin College of Dentistry, Ziauddin University, Karachi, Sindh-Pakistan

²Department of Orthodontics, Ziauddin University, Karachi, Sindh-Pakistan

³Department of Oral Biology, Ziauddin College of Dentistry, Ziauddin University, Karachi, Sindh-Pakistan

⁴Department of Forensic Medicine and Toxicology, Ziauddin University, Karachi, Sindh-Pakistan

Correspondence: sarwat.memon@zu.edu.pk

doi: 10.22442/jlumhs.2024.01112

Received: 01-03-2024

Revised: 04-09-2024

Accepted: 06-09-2024

Published Online: 18-10-2024



using Clear Canvas RIS/PACS Version 2.0 12729. 37986 SP1 Software.

Digital OPGs of lower third molar teeth from the left side of the mandible of individuals aged 18-40 were evaluated. The Digital OPGs with good contrast, radiographically selected teeth with good quality images and good morphology of the tooth with complete root formation, i.e., left lower third molar teeth, were included in this study. Digital OPGs of the following patients were excluded in cases where none of the teeth to be studied was available, the tooth under study had a filling, the tooth under study was either inflamed or decayed or the tooth under study presenting with anomalies (fused roots, single roots and dilacerations). New and ongoing patients who came to the Orthodontics department and fulfilled the inclusion and exclusion criteria were selected for study after informed consent was obtained.

The sample size was 240 as per the calculation of the OpenEpi calculator based on a 95% confidence interval with a 7% margin of error, but 260 digital orthopantomograms (OPGs) were taken for study purposes to reduce the error and to increase the validity of the study. The samples were recruited using a non-probability consecutive sampling technique from the Department of Orthodontics, Ziauddin University Hospital, Clifton campus, and Karachi X-rays Center in Karachi, Pakistan.

The research was carried out with the approval of Ziauddin University ERC letter No. 5850822MSOM.

Stage classification was used by Olze et al. to evaluate the radiographic RPV and PLV of the lower third molar teeth with wholly formed roots and apical closures from the left side of the mandible by assessing them on the digital OPGs.

The four stages, according to Olze et al. classification for radiographic RPV, were as follows:









- "Stage 0 = the lumen of all root canals is visible to the apex of the root.
- Stage 1 = the lumen of one root canal is not fully visible to the apex of the root.
- Stage 2 = the lumen of two root canals is not fully visible to the apex, or one canal is not at full length.
- Stage 3 = the lumen of two root canals is not visible in full length."³ (Figure 1)

The four stages, according to Olze et al.⁶ classification for radiographic PLV, were as follows:

- Stage 0 = the periodontal ligament is visible along the entire length of all roots.
- Stage 1 = The periodontal ligament is not visible in one root from the apex to more than half of the root.
- Stage 2 = The periodontal ligament is not visible along almost the entire length of one root, along part of the root in two or both roots.
- Stage 3 = the periodontal ligament is not visible along the two roots⁴. (Figure 1)

Data were analyzed using SPSS software version 25. The normality of data was assessed using the Shapiro

Figure 1: Diagrammatic representation of stage classification for radiographic root pulp visibility and periodontal ligament visibility in lower third molar teeth; Modified from Olze et al.⁶; RPV, root pulp visibility; PLV, periodontal ligament visibility

Radiographic RPV and PLV Stages	Diagrammatic Representation of Stages of Radiographic RPV	Diagrammatic Representation of Stages of Radiographic PLV
STAGE 0		
STAGE 1		
STAGE 2		
STAGE 3		

-Wilk test. Quantitative data such as chronological age was analyzed through the median and Interquartile range [IQR]. Qualitative data like sex and radiographic RPV and PLV stages were presented through frequency and percentage. The chi-square test was applied to find the association between different stages of radiographic RPV and PLV with the age and sex of the individuals. P-value less than or equal to 0.05 was considered statistically significant ($P \leq 0.05$). Mean ages for radiographic RPV and PLV of lower third molar teeth were compared at different stages using an Independent samples t-test, taking P-value less than or equal to 0.05 as statistically significant ($P \leq 0.05$).

RESULTS

The demographic characteristics of participants are shown in Figure 2. The ages of the participants were divided into three groups, with the first group ranging from 18-25 years, the second group ranging from 26-32 years and the third group ranging from 33-40 years. The comparison of stages of radiographic RPV and PLV was made with each group, as shown in Table I. Around 90.9% of participants ranging from 18-25 years were found to be in stage 0 for radiographic RPV and radiographic PLV. Whereas 78.6% of participants with ages ranging from 26-32 years were found to be in stage 0 for radiographic RPV and 68.6% for radiographic PLV; for ages ranging from 33-40 years, 42.3% participants were found to be in stage 0 for radiographic RPV and 46.2% participants

Figure II: Demographic characteristics of participants; A- periodontal ligament visibility and root pulp visibility of 3rd molar teeth; B- age category, the groups the ages were divided; C- sex of the patient

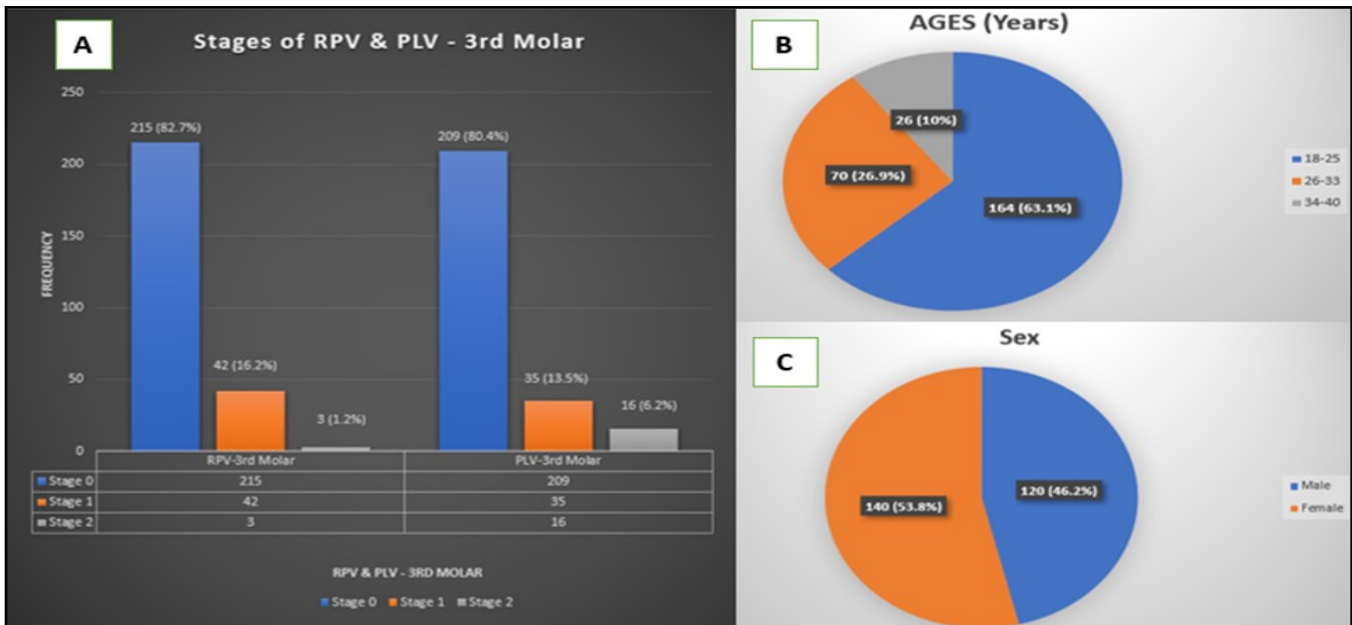


TABLE I: COMPARISON OF STAGES OF RADIOGRAPHIC ROOT PULP VISIBILITY AND PERIODONTAL LIGAMENT VISIBILITY OF LOWER 3RD MOLAR TEETH WITH AGE GROUPS AND SEX

Age	Radiographic root pulp visibility of lower 3 rd molar teeth					Radiographic periodontal ligament visibility of lower 3 rd molar teeth				
	Stage 0	Stage 1	Stage 2	Total	P-value	Stage 0	Stage 1	Stage 2	Total	P-value
18-25	149 (90.9%)	15 (9.1%)	0 (0%)	164 (100%)	<0.001	149 (90.9%)	14 (8.5%)	1 (0.6%)	164 (100%)	<0.001
26-32	55 (78.6%)	13 (18.6%)	2 (2.9%)	70 (100%)		48 (68.6%)	15 (21.4%)	7 (10%)	70 (100%)	
33-40	11 (42.3%)	14 (53.8%)	1 (3.8%)	26 (100%)		12 (46.2%)	6 (23.1%)	8 (30.8%)	26 (100%)	
Sex	Radiographic root pulp visibility of lower 3 rd molar teeth					Radiographic periodontal ligament visibility of lower 3 rd molar teeth				
	Stage 0	Stage 1	Stage 2	Total	P-value	Stage 0	Stage 1	Stage 2	Total	P-value
Male	100 (83.3%)	18 (15%)	2 (1.7%)	120 (100%)	0.704	95 (79.2%)	16 (13.3%)	9 (7.5%)	120 (100%)	0.705
Female	115 (82.1%)	24 (17.1%)	1 (0.7%)	140 (100%)		114 (81.4%)	19 (13.6%)	7 (5%)	140 (100%)	

Chi-square test; level of significance less than or equal to 0.05 (P ≤ 0.05)

TABLE II: DESCRIPTIVE ANALYSIS OF CHRONOLOGICAL AGE FOR DIFFERENT STAGES OF RADIOGRAPHIC ROOT PULP VISIBILITY AND PERIODONTAL LIGAMENT VISIBILITY OF LOWER 3RD MOLAR

Stages	Radiographic root pulp visibility of lower 3 rd molar teeth				Radiographic periodontal ligament visibility of lower 3 rd molar teeth			
	N	Min age	Max age	Mean (SD)	N	Min age	Max age	Mean (SD)
0	215	18	39	24.26 (4.626)	209	18	40	24.16 (4.785)
1	42	18	40	29.71 (6.620)	35	18	40	28.31 (5.769)
2	3	28	40	32.00 (6.928)	16	20	40	32.44 (4.899)

N: number of individuals with selected tooth, Min: minimum, Max: maximum, SD: standard deviation

for radiographic PLV; the results were found to be statistically significant with the P-value less than 0.05.

Table I also shows the comparison of stages of radiographic RPV and PLV with sex (both male and female), and results were statistically insignificant with a P-value more than 0.05. Descriptive analysis of chronological age for different stages of radiographic

RPV and PLV of lower third molar teeth was performed; the data is recorded in Table II, showing statistically significant results (P-value less than 0.05) with stage 0 and stage 1 showing the minimum age for both radiographic RPV and PLV was 18 years of age. For stage 2, the age range was 28 years for radiographic RPV and 20 years for radiographic PLV.

DISCUSSION

Every individual's teeth are unique and show a complex and dynamic growth process in correlation to increasing age⁷. Previous data show that ethnicity has a vital role in the development of teeth in tooth development; hence, reference data specific to a particular population could increase the accuracy of dental age assessment⁸. The staging method suggested by Oze et al. can be used for the maxillary teeth due to the presence of anatomical noises³.

According to our study, individuals found in stage 1 for radiographic PLV are at least 18 years of age; however, in the study conducted on the Mysore population by Patil et al.⁹ in 2021 where, they aimed to assess the reliability of the age estimation method using the radiographic visibility of periodontal ligament surrounding the roots of completely erupted mandibular 3rd molar, it was concluded that this technique could be used for determining age above 19 years as stage 1 individuals were above 19 years of age⁹, this difference in results could be due to the ethnicity. In our study, an individual found in stage 2 for radiographic PLV is above 20 years of age; however, in a study conducted on the northern Thai population with ages ranging from 16-26 years using 800 digital OPGs to analyze the radiographic visibility of the periodontal ligament in completed root formation of lower third molars, it was concluded that periodontal ligament visibility found to be in stage 2, it may confirm that the individual is at least 18 years of age¹⁰. This difference in results could be due to the difference in the lower and upper age ranges considered in both studies. In our research, Stages 0 and 1 were first achieved at 18 years of age and stage 2 was completed at 20 years of age for radiographic PLV. Guo Y et al.⁸ conducted a study in 2017 on the northern Chinese population where 1300 conventional OPGs with the age range of 15 to 40 years were evaluated. The aim was to determine if Olze et al.'s. Stages for radiographic PLV could be used for the 18-year threshold. Stage 1 was found at 18.52 years in males and 19.59 years in females. Hence, they concluded that at stage 1, it is possible to say that an individual has reached the 18-year threshold⁸. This variation could be due to differences in sample size and ethnicity of the population under study.

Gok E et al.,¹¹ in 2020, conducted a study where 9059 digital OPGs were analyzed to assess radiograph RPV of lower third molar teeth of both males and females aged 18 to 40 years for age estimation. The findings showed no statistically significant difference between stage values in different sexes and age groups. The findings and results align with our study, which shows no significant difference between stage values in different sexes and age groups. Balla et al. investigated the lower second molar for radiographic RPV using the stage classification of Olze A et al.⁶ in the lower second molar for age assessment. 936 OPGs were evaluated for both male and female

individuals with age ranging from 14 to 22 years. Stage 3 was not found in any case similar to our study. They also concluded that stage 2 was to be found at 18.6 years and 15.2 years in males and females at the earliest 12 age. Comparatively, in our study population, stage 2 was first achieved at 28 years of age for radiographic RPV; this could be because of the difference between the sample size and the study populations' lower and upper age limits. Gunacar et al.¹³ studied 429 mandibular third molars intending to assess the reliability of OPG through the radiographic root pulp staging method using cone beam computed tomography (CBCT) verification for age estimation. They concluded that Stage 3 was absent at age 18 and under for CBCT and OPG radiographs, which might have a forensic value for the RPV age estimation method. In the Gunacar DN 2022¹³ study, the upper age limit extended beyond 40 years of age, and this could be one of the reasons, apart from ethnic differences, why Stage 3 was not found in our study. Serin CS 2023¹⁴, concluded a similar result to our research, stating that there was the absence of stage 3 when 699 cone beam computed tomography (CBCT) images were evaluated for radiographic RPV of lower second molar for age estimation purposes using 699 CBCT of individuals aged between 15 to 75 years.

This study did not compare male and female results, and the individuals were not equally distributed among age ranges and sex groups. An imaging system that uses 2-D methods has limitations due to super-positioning, magnification, and/or distortions of structures being examined.

CONCLUSION

In a subset of the Pakistani population, when an individual is assessed for radiographic root pulp visibility (RPV), stage 0 and stage 1 indicate that the individual is 18 or above, and stage 2 indicates that the individual is at least 28 years of age. However, for radiographic periodontal ligament visibility (PLV), it can be said that the individual has attained 18 years of age if found in stage 0 and stage 1. Moreover, if the individual is found at stage 2, the individual is at least 20 years of age.

RECOMMENDATIONS

3-D imaging systems such as cone beam computed tomography (CBCT) should be utilized to evaluate these characteristics since it is widely used in dentistry and forensic odontology to overcome the limitations of 2-D imaging systems. Future studies should investigate the influence of different ethnicities, dietary habits, clenching and grinding habits, and socio-economic status on the radiographic RPV and PLV of third molar teeth. It is recommended that the radiographic RPV and PLV for both males and females be evaluated separately for more accurate results. There should be an extension in the lower age range limit by including more data on individuals younger than 18.

Ethical permission: Ziauddin University, Karachi, Pakistan, ERC letter No. 5850822MSOM.

Informed Consent: Informed consent was obtained from the patients before their radiographs were used for analysis.

Conflict of Interest: No conflicts of interest, as stated by authors.

Financial Disclosure / Grant Approval: No funding agency was involved in this research.

Data Sharing Statement: The corresponding author can provide the data proving the findings of this study on request. Privacy or ethical restrictions bound us from sharing the data publicly.

AUTHOR CONTRIBUTION

Sami M: Drafting the article and reviewing it critically for important intellectual content

Memon S: Substantial contributions to the conception and design of the work, agreement to be accountable for all aspects of the work in ensuring that questions are related to accuracy.

Sahar F: Substantial contributions to the conception and design of the work.

Hassan Q: Final approval of the version to be published.

REFERENCES

1. Tangkabutra S, Alzoubi E, Roberts G, Lucas V, Camilleri S. Root canal width as a mandibular maturity marker at the 18-year threshold in the Maltese population. *Int J Legal Med.* 2022; 136(6): 1667-74. doi: 10.1007/s00414-022-02868-0. Epub 2022 Jul 19.
2. Helmy MA, Osama M, Elhindawy MM, Mowafey B, Taalab YM, Abd ElRahman HA. Volume analysis of second molar pulp chamber using cone beam computed tomography for age estimation in Egyptian adults. *J Forensic Odontostomatol.* 2020; 38(3): 25-34.
3. Olze A, Solheim T, Schulz R, Kupfer M, Schmeling A. Evaluation of the radiographic visibility of the root pulp in the lower third molars for the purpose of forensic age estimation in living individuals. *Int J Legal Med.* 2010; 124(3): 183-6. doi: 10.1007/s00414-009-0415-y. Epub 2010 Jan 29.
4. Olze A, Solheim T, Schulz R, Kupfer M, Pfeiffer H, Schmeling A. Assessment of the radiographic visibility of the periodontal ligament in the lower third molars for the purpose of forensic age estimation in living individuals. *Int J Legal Med.* 2010; 124(5): 445-8. doi: 10.1007/s00414-010-0488-7. Epub 2010 Jul 11.
5. Akkaya N, Yılcı HÖ, Boyacıoğlu H, Göksülük D, Özkan G. Accuracy of the use of radiographic visibility of root pulp in the mandibular third molar as a maturity marker at age thresholds of 18 and 21. *Int J Legal Med.* 2019; 133(5): 1507-15. doi: 10.1007/s00414-019-02036-x. Epub 2019 Mar 13.
6. Olze A, Solheim T, Schulz R, Kupfer M, Schmeling A. Evaluation of the radiographic visibility of the root pulp in the lower third molars for the purpose of forensic age estimation in living individuals. *Int J Legal Med.* 2010; 124(3): 183-6. doi: 10.1007/s00414-009-0415-y. Epub 2010 Jan 29.
7. Verma M, Verma N, Sharma R, Sharma A. Dental age estimation methods in adult dentitions: An overview. *J Forensic Dent Sci.* 2019; 11(2): 57-63. doi: 10.4103/jfo.jfds_64_19. Epub 2020 Jan 24.
8. Guo Y-c, Li M-j, Olze A, Schmidt S, Schulz R, Zhou H et al. Studies on the radiographic visibility of the periodontal ligament in lower third molars: can the Olze method be used in the Chinese population? *Int J Legal Med.* 2018; 132(6): 617-22. doi: 10.1007/s00414-017-1664-9. Epub 2017 Aug 15.
9. Patil K, VG M, Chandran P, Penumatsa B, Daggalli N, CJ S. Age Estimation Using the Radiographic Visibility of the Periodontal Ligament in Mandibular Third Molars in Mysore Population-A Retrospective Study. *Indian J Forensic Med Toxicol.* 2021; 15(3): 269-275. doi: 10.37506/ijfamt.v15i3.15316.
10. Tantanapornkul W, Kaomongkolgit R, Tohnak S, Deepho C, Chansamat R. Chronological age assessment, based on the radiographic visibility of the periodontal ligament in lower third molars in a group of Thai sample. *J Forensic Odontostomatol.* 2021; 39(2): 32-37.
11. Gok E, Fedakar R, Kafa IM. Usability of dental pulp visibility and tooth coronal index in digital panoramic radiography in age estimation in the forensic medicine. *Int J Legal Med.* 2020; 134(1): 381-92. doi: 10.1007/s00414-019-02188-w. Epub 2019 Nov 13.
12. Suvarna M, Balla SB, Chinni SS, Reddy SP, Gopalaiah H, Pujita C et al. Examination of the radiographic visibility of the root pulp of the mandibular second molars as an age marker. *Int J Legal Med.* 2020; 134(5): 1869-73. doi: 10.1007/s00414-020-02347-4. Epub 2020 Jun 22.
13. Gunacar DN, Bayrak S, Sinanoglu EA. Three-dimensional verification of the radiographic visibility of the root pulp used for forensic age estimation in mandibular third molars. *Dentomaxillofac Radiol.* 2022; 51(3): 20210368. doi: 10.1259/dmfr.20210368. Epub 2021 Nov 17.
14. Canpolat SS, Bayrak S. Evaluation of radiographic visibility of root pulp in mandibular second molars using cone beam computed tomography images for age estimation. *Forensic Sci Med Pathol.* 2024; 20(1): 8-13. doi: 10.1007/s12024-023-00594-6. Epub 2023 Feb 28.

