

Immunoexpression of Nestin and Ki-67 in Astrocytoma in a Single Tertiary Health Care Centre

Prih Bashir^{1*}, Noshaba Rahat¹, Humera Shahzad¹, Asma Jalbani¹, Farah Siraj¹, Zumrud Momin¹

ABSTRACT

OBJECTIVE: To evaluate the prognostic significance of Nestin and Ki-67 expression in Astrocytoma across different grades.

METHODOLOGY: A retrospective cross-sectional analysis was conducted at the Histology Department, Basic Medical Sciences Institute, JPMC Karachi, between October 2019 and September 2022. In this study, Nestin and KI-67 immunohistochemistry expression was assessed in 60 Astrocytoma, and its expression was seen with different degrees of Astrocytoma.

RESULTS: Nestin positivity was found in 86.7% of cases of Astrocytoma. The immune-reactive score for Nestin staining in different stages of Astrocytoma was shown to have a significantly significant P-value. 41.7% of cases of Astrocytoma were found to have a KI-67 labeling index; all high-grade Astrocytoma had a high labeling index of Ki-67. It was demonstrated that the immune-reactive score for Ki-67 staining at various phases of Astrocytoma had a statistically significant P-value.

CONCLUSION: We discovered that Nestin and Ki-67 were expressed in Astrocytoma and that the expression of both immune markers rose with tumor grade. Nestin and Ki-67 serve as a helpful marker for assessing the Astrocytoma's prognosis. These findings may be used to determine the best course of action for Astrocytoma therapy.

KEYWORDS: Nestin, Ki-67, Astrocytoma, immunohistochemistry, WHO grading, prognosis.

INTRODUCTION

Central nervous system (CNS) tumors can be either benign or malignant. These include meningiomas, medulloblastomas, gliomas, and embryonal tumors¹. Approximately 27% of all primary brain tumors are classified as diffuse gliomas. Diffuse gliomas arise from glial cells, which provide support and protection for neurons².

In Pakistan, gliomas are among the most common types of brain tumors treated at Shaukat Khanum Memorial Cancer Hospital. In 2020, gliomas accounted for over half of all brain tumor cases reported at the facility³. Research indicates that males have a 50% higher incidence of gliomas than females, particularly during adulthood. This disparity in prevalence suggests that gender may play a role in the risk factors associated with glioma development. Several factors could contribute to this increased incidence in males, including genetic, hormonal, and environmental influences⁴.

Various factors, including genetics, race, ethnicity, and gender¹, can influence central nervous system (CNS) tumors. The risk of developing Astrocytoma, in particular, is elevated by exposure to ionizing radiation and certain genetic conditions, such as Lynch

syndrome, Li-Fraumeni syndrome, Cowden syndrome, Turcot syndrome, and Neurofibromatosis type I⁵. In general, males are more frequently diagnosed with malignant brain tumors compared to females. Conversely, low-grade gliomas occur with similar frequency in both sexes⁶.

Astrocytoma grading and classification

Astrocytomas are more commonly observed in the cerebral hemispheres, particularly in adult males. In children, they can be located in the brain stem and the cerebral halves of the brain.

In 2021, the World Wellbeing Association (WHO) mentioned their astrocytoma grading system, which ranges from grade 1 to grade 4⁷.

Grade I: Astrocytomas are harmless and most commonly affect teenagers.

Grade II: Nuclear atypia is the only symptom of Astrocytoma, which primarily affects adults.

Grade III: The features are mitosis, nuclear atypia and anaplasia.

Grade IV: It is characterized by necrosis, microvascular enlargement, nuclear atypia or mitosis.

There has been increasing evidence in recent years that cancer stem cells (CSCs) play a role in the genesis of malignancies. Researchers have found that some peptides can attach to undifferentiated glioma progenitor cells and detect surface Nestin. Radiopharmaceuticals targeting Nestin, such as peptides, monoclonal antibodies, or cytotoxic chemicals, can eliminate these cells⁸. While Nestin-targeted therapies are still largely experimental, ongoing research aims to evaluate their efficacy and safety in clinical trials.

¹Department of Pathology, Basic Medical Sciences Institute, Jinnah Postgraduate Medical Center, Karachi, Pakistan

Correspondence: drprihbashir@gmail.com

doi: 10.22442/jlumhs.2024.01155

Received: 30-05-2024

Revised: 12-09-2024

Accepted: 20-09-2024

Published Online: 24-10-2024



A potential marker for CSCs is Nestin, an intermediate filament protein. Many stem cells, including neural stem cells, express nestin^{9,10}. Resistance to cancer therapy appears closely linked to cancer stem cells⁹. The heart, non-hematopoietic bone marrow, testicles, pancreatic islets, hair follicles, hepatic cells, skeletal muscle satellite cells, developing myotomes and renal progenitors are among the tissues and stem or progenitor cells that express it^{8,9}. According to Yamagishi, Angiogenesis, proliferation, and tumor infiltration have been linked with Nestin as a biomarker for CSCs¹⁰.

Neuroectodermal neuroepithelial cancers that were neuronal, astrocytic, oligo-astrocytic, oligodendroglial and neuronalglial were shown to have the nestin protein⁸. Numerous malignancies, including glioma, melanoma, osteosarcoma, neuroblastoma, pancreatic cancer, tumor vasculature and prostate cancer, appear to have nestin expression as a contributing factor to their pathogenesis^{9,10}.

It has been demonstrated that Nestin inhibits Gli3, a regulator of the hedgehog signaling system, which is linked to the growth and metastasis of cancers. Nestin tail enhances Gli3 target genes, such as Gli1 and PTCH, by interacting with Gli3 and preventing its nuclear translocation¹⁰.

It is claimed by Andrés-Sanchez N 2022¹¹ that proliferating cells have the Ki-67 antigen and that lack of Ki-67 results in cell death or arrest. Cidado J et al.¹² reports that Ki-67 expression is low or absent in normal tissues with live proliferating cells, but the integrity of this is still in question. Additionally, he found many aggressive cancer cells overexpress Ki-67, making it a potential cancer target.

In malignant tumors, Ki-67 expression is linked to internal cell proliferation, indicating tumor aggressiveness. 10-14 percent of Ki-67 immunostaining-positive cells are considered high-risk cancer. Particular breast, lung, cervical, urinary tract, lymphoma, central nervous system, prostate and soft tissue malignancies may be accurately predicted, treated, and prognoses using Ki-67¹³.

The rationale for doing this study was to assess the immune-histochemical expression of Nestin and Ki-67: This research aims to systematically evaluate the levels of Nestin and Ki-67 proteins in astrocytoma tumors through immune-histochemical techniques. These biomarkers will be analyzed to understand their distribution and intensity in different grades of Astrocytoma. **To correlate these biomarkers with tumor grading:** The study seeks to determine how variations in the expression of Nestin and Ki-67 correlate with the grade of Astrocytoma, ranging from lower to higher; this will help understand the relationship between these biomarkers and tumor severity. **To evaluate the prognostic significance of Nestin and Ki-67:** By analyzing the expression patterns of Nestin and Ki-67.

METHODOLOGY

Our study was a retrospective cross-sectional analysis of Astrocytoma that was identified histopathologically. The cases were taken from the Department of Histology, BMSI, JPMC Karachi, between October 2019 and September 2022. We assessed Nestin and Ki-67 expression in 60 cases of Astrocytoma using non-probability convenience sampling.

The study included all histologically confirmed Astrocytoma specimens that were formalin-fixed and paraffin-embedded. Tumors other than Astrocytoma and poorly fixed and inadequate tissue specimens were not included in the immunohistochemistry analysis.

Staining was done on sections mounted on Poly-L-lysine-coated slides. The marker's technique was performed according to the manufacturer's instructions. The tissue sections were dewaxed and rehydrated with xylene, lowering alcohol concentrations. Antigen unmasking was carried out using a steamer and tris HCl buffer (PH 9.0). After blocking peroxidase, the sections were stained with the Nestin monoclonal primary antibody from Cell Marque Corporation is catalogued as REF 388M-18 and for Ki-67 with Dako Corporation's mouse monoclonal primary antibody (catalogue no. REF IR626). Following secondary antibody incubation, sections were coated with Di-aminobenzidine chromogen. A section of malignant melanoma tissue was used as a positive control for Nestin and an Appendix wall section for Ki-67. Two pathologists examined every slide.

Nestin stains the cytoplasm in malignant cells, while Ki-67 stains the nucleus. An immune-reactive score (IRS) was used to assess Nestin's staining further. The intensity score ranges from No staining = 0, Weak staining = 1, Medium staining = 2 and Strong staining = 3, indicating the proportion of cells with a positive stain. The percentage score (PS) reflects the staining intensity, which has values of 0 for negative tumor cells, 1 for <30% positive tumor cells, 2 for 30%–60% positive tumor cells and 3 for more than 60% positive tumor cells. The intensity score (IS) and the percentage score (PS) are multiplied to get an immune-reactive score. Regarding expressiveness level, a score of 1 to 3 is labeled poor, 4 to 6 is labeled moderate, and 7 to 9 is labeled strong¹⁴.

The amount of cancer cells that stain positive was used to evaluate the expression of Ki-67 semi-quantitatively. Ten percent or less of the labeled cells were determined to be negative. Ten percent or more of the stained cells were considered positive¹⁵.

Data collection and statistical analysis were conducted using SPSS 21. The chi-square test was employed to establish statistical significance when $P \leq 0.05$.

RESULTS

Table I demonstrates Nestin's immune reactivity according to the Astrocytoma grades. The Pearson

Chi-square test revealed a statistically significant correlation between Nestin immune reactivity and Astrocytoma grades ($p < 0.001$).

Table II demonstrates the immunoreactivity to Ki-67 based on the grades of Astrocytoma. All Pearson Chi-Square tests found a strong correlation between Astrocytoma grades and Ki-67 ($p < 0.001$).

DISCUSSION

In our study, we received 60 cases of Astrocytoma, of which 40 were low-grade and 20 were high-grade Astrocytoma. Most Astrocytomas were in the third decade of life, followed by the second decade, and men were more frequently affected.

Our research found that higher grades of Astrocytoma

TABLE I: NESTIN IMMUNO-REACTIVITY IN VARIOUS GRADES OF ASTROCYTOMA

Morphology	Grades	Nestin Immuno-reactivity				Total	P-value
		Negative Staining n(%)	Weak Staining n(%)	Medium Staining n(%)	Strong Staining n(%)		
Astrocytoma	GRADE-1 (pilocytic)	2(3.3)	9(15)	5(8.3)	0(0)	16(26.7)	<0.001*
	GRADE-2 (diffuse)	3(5)	11(18.3)	8(13.3)	2(3.3)	24(40)	
	GRADE-3 (anaplastic)	1(1.7)	-	-	5(8.3)	6(10)	
	GRADE-4 (Glioblastoma Multiformis)	2(3.3)	-	-	12(20)	14(23.3)	
Total		8(13.3)	20(33.3)	13(21.7)	19(31.7)	60(100)	

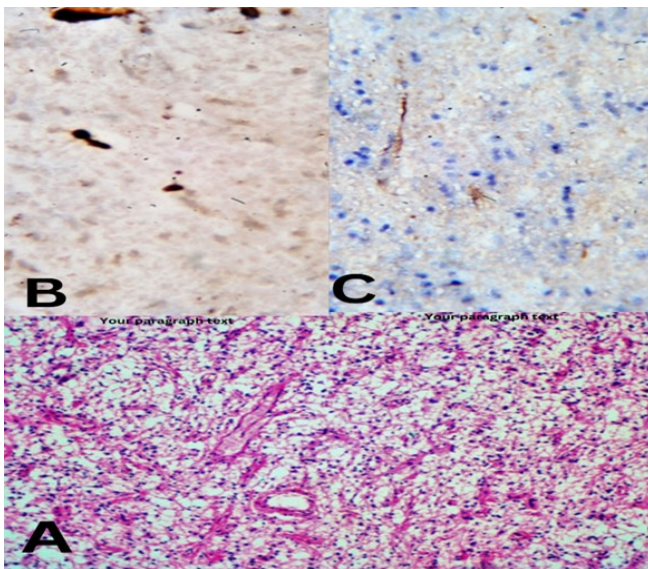
*Using the Pearson Chi-Square test, statistically significant was $p < 0.05$.

TABLE II: IMMUNO-REACTIVITY OF KI-67 IN DIFFERENT GRADES OF ASTROCYTOMA

Morphology	Grades	KI-67 IMMUNOREACTIVITY		Total	P-value
		Positive (>10%)	Negative (<10%)		
Astrocytoma	GRADE-1 (Pilocytic)	0 (0)	16 (26.7)	16 (26.7)	<0.001*
	GRADE-2 (Diffuse)	5 (8.3)	19 (31.7)	24 (40)	
	GRADE-3 (Anaplastic)	6 (10)	0 (0)	6 (10)	
	GRADE-4 (Glioblastoma Multiformis)	14 (23.3)	0 (0)	14 (23.3)	
Total	Total	25 (41.7)	35 (58.3)	60 (100)	

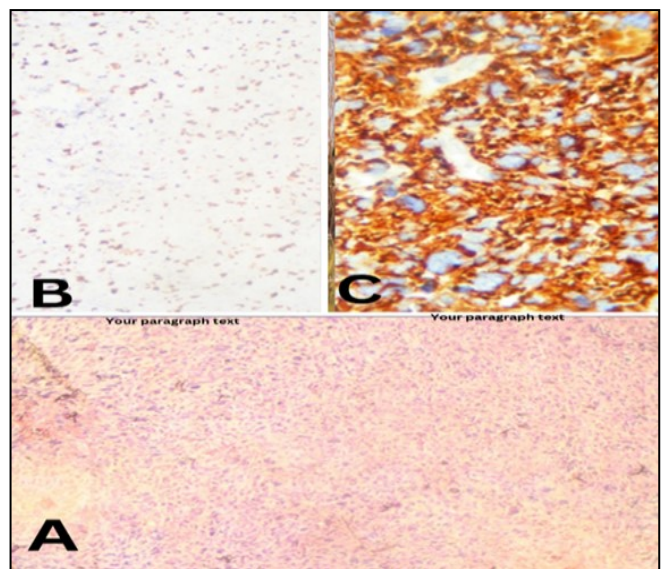
*Using the Pearson Chi-Square test, statistically significant was $p < 0.05$.

FIGURE I: PILOCYTIC ASTROCYTOMA



A) Pilocytic Astrocytoma grade I (4X),
 B) Low <10% Ki-67 in Pilocytic Astrocytoma (10X),
 C) Mild expression of Nestin in Pilocytic Astrocytoma (10X)

FIGURE II: GLIOBLASTOMA MULTIFORMIS



A) Glioblastoma Multiformis grade IV (4X),
 B) High >10% Ki-67 in Glioblastoma Multiformis (10X)
 C) Strong expression of Nestin in Glioblastoma Multiformis (40X)

are associated with increased Nestin and Ki-67 immuno-reactivity, indicating a higher proliferation rate of the tumor cells. The study also noticed that the Nestin and Ki-67 immuno-reactivity correlated significantly with the grade of Astrocytoma. This information could be valuable for clinicians in determining the tumor's aggressiveness and planning appropriate treatment strategies.

In the current investigation, 8(13.3%) Astrocytomas showed negative staining. Comparably, only 3/48 (6.25%) of the Astrocytoma in the study by Abdulkareem RM 2019¹⁴ showed negative staining, less than in our investigation. A result discovered by Woo CG 2021¹⁶ showed that 32(34.8%) of the cases showed negative staining, which was more significant than in our study.

The current investigation showed weak staining in 20 (33.3%) Astrocytomas. A study reveals poor staining in 9(18.75%) cases of Astrocytoma, which is lower than our study¹⁴. Another study reveals poor staining in 22(23.9%) glioma patients¹⁶. Additionally, 13 (21.7%) of the Astrocytomas had moderate Nestin staining, according to our research. However, 25 (28.2%) of the astrocytes in the study by Abdulkareem RM 2019¹⁴ exhibit considerable Nestin staining, which is somewhat higher than in our investigation.

Nineteen (31.7%) of the Astrocytomas in our investigation had intense staining. Likewise, 11 (22.9%) Astrocytomas have significant staining, according to Abdulkareem RM 2019¹⁴. Another study states that Nestin staining is observed in 35(28%) gliomas, which is greater than our research since they incorporate all the gliomas; this is following the current study¹⁷.

Astrocytoma grades and Nestin immunoreactivity were significantly correlated. High-grade tumors exhibit substantial Nestin expression, according to our research. Rehfeld M et al.¹⁸ found a similar result, indicating that Nestin immunoreactivity strongly correlates with Astrocytoma grades.

This research (2/24) found that 3.3% of grade II Astrocytoma had high Nestin expression. According to Rushing EJ 2010¹⁹, 1.37% of grade II astrocytoma have significant positive for Nestin, which is consistent with our findings. According to Dahlrot RH et al.²⁰, patients with high levels of Nestin and WHO grade II malignancies had a considerably worse progression-free survival (PFS) rate. It can be explained by diffuse Astrocytoma, which has a bad prognosis due to elevated Nestin expression. Furthermore, according to Dahlrot RH et al.²⁰, greater expression of Nestin is associated with worse patient prognosis as Astrocytoma grades grow.

Our research shows (2/14) of GBM grade 4 and 1/6 of Anaplastic Astrocytoma grade 3 showed no staining. According to the study by Abdulkareem RM 2019¹⁴ three of the eleven (grade III) Anaplastic Astrocytoma cases exhibit moderate staining. In contrast, eight cases exhibit strong staining and of the five (grade IV) GBM cases, two exhibit moderate staining and three

exhibit weak staining. It was discovered that weak Nestin positivity accounted for around half of all Anaplastic Astrocytoma¹⁶. Negative staining may occur when antigens are removed from the tissue during tissue processing. No research has demonstrated that Astrocytoma in grades III and IV has no Nestin staining.

Previous research findings indicate that glioblastomas (Astrocytoma classified as GBMs; WHO grade IV) have greater Nestin expression levels than low-grade gliomas (WHO grades II-III). Additionally, research has shown that increased Nestin expression is also linked to lower survival periods when low-grade invasive gliomas (grade II), anaplastic gliomas (grade III), or GBMs (grade IV) are combined into a single category²¹.

We found that Ki-67 is a valuable tool for more precisely differentiating Glioblastoma from Diffuse Astrocytoma and Pilocytic Astrocytoma. Of the grade I (16/16) cases, 26.7%, the Ki-67 labeling index was low, at less than 10%. Muslim LM 2021²² found a low labeling index of 10/10 (22.2%), similar to our results. Of the 24 instances of grade II, around 19 (31.7%) had a low labeling index, and 5 (8.3%) had a high (>10%) labelling index. Comparable to our research, Muslim LM 2021²² findings indicate that 3/24 (6.6%) patients have a high labeling index and 21/24 (48.9%) cases have a low (<10%) ki-67 labeling index²².

In each case of grade III 6/6 (10%) and grade IV 14/14 (23.3%), the labeling index was high (>10%). These findings are consistent with Enestrom S 1998 and Torp SH 2002^{23,24}.

Out of 24 grade II Diffuse Astrocytoma (40%), 5(8.3%) had a high ki-67 labeling index (>10%). Research that reported one case of Diffuse Astrocytoma with a 12% ki-67 Labeling index also found similar results to ours²⁵; this might be because slow-growing cancers eventually exhibit more aggressive biology, as Hirtz A 2020⁵ suggested.

The grades of Astrocytoma and Ki-67 have a substantial association. According to reports, the Ki-67 Labeling index rises as the WHO grade does; this explains why the median Ki-67 Labeling index for tumors with WHO grades II, III, and IV is 2.7%, 6.4%, and 27.5%, respectively. Overall survival of IDH-wild-type glioblastomas, which are already aggressive and have been histologically diagnosed, cannot be estimated by the Ki-67 Labeling Index²⁶.

Glioblastoma diagnosis cannot be made using the Ki-67 Labeling Index alone. Additionally, there was an overlap in the Ki-67 Labeling Index grades. A problematic diagnosis may arise from glioblastoma multiformis, which can have Ki-67 Labelling Index values as low as Grade II tumors²⁷.

CONCLUSION

We discovered that Nestin was expressed in Astrocytomas and that the expression of Nestin rises with tumor grade. However, we may conclude that Nestin is a helpful marker for assessing the prognosis

of Astrocytoma. We also determine that Ki-67 expression is frequently employed as a proliferation marker and therapeutic agent in regular pathological examinations because it is highly correlated with the development and proliferation of tumor cells. The majority of high-grade tumors had strong expression of Ki-67 in Astrocytoma. These data can be used to determine the best course of therapy for Astrocytoma. Further investigation of ki-67 as a therapeutic target in cancer treatment will undoubtedly lead to a rise in therapeutic success.

ACKNOWLEDGMENT

The authors acknowledge the support and facilities of Jinnah Postgraduate Medical Center Karachi. The authors would also want to express their gratitude to the writers, editors, and publishers of all the books, journals, and articles that served as the basis for this article.

Ethical permission: Jinnah Post Graduate Medical Center Karachi IRB letter No. F.2-81/2022-GENL/272/JPMC.

Conflict of Interest: No conflicts of interest, as stated by authors.

Financial Disclosure / Grant Approval: No funding agency was involved in this research.

Data Sharing Statement: The corresponding author can provide the data proving the findings of this study on request. Privacy or ethical restrictions bound us from sharing the data publicly.

AUTHOR CONTRIBUTION

Bashir P: Devised the idea and wrote the manuscript.

Rahat N: Write up and proofread

Shahzad H: Tabulation and proofreading

Jalbani A: Editing, statistics and data collection.

Siraj F: Literature search and data collection

Momin Z: Literature search and statistical analysis.

REFERENCES

- Salari N, Ghasemi H, Fatahian R, Mansouri K, Dokaneheifard S, Shiri MH et al. The global prevalence of primary central nervous system tumors: a systematic review and meta-analysis. *Eur J Med Res.* 2023; 28(1): 39. doi: 10.1186/s40001-023-01011-y.
- Mirchia K, Sathe AA, Walker JM, Fudym Y, Galbraith K, Viapiano MS et al. Total copy number variation as a prognostic factor in adult astrocytoma subtypes. *Acta Neuropatholog Commun.* 2019; 7: 8. doi: 10.1186/s40478-019-0746-y.
- Mahmood S, Faraz R, Yousaf A, Quader A, Asif H, Atif A et al. Annual Cancer Registry Report 2017 of the Shaukat Khanum Memorial Cancer Hospital & Research Center, Pakistan. Shoukat Khanam Memorial Cancer Hospital Research Centre. 2018. Available from: <https://shaukatkhanum.org.pk/wp-content/uploads/2018/08/acrr-2017.pdf>.
- Miller KD, Ostrom QT, Kruchko C, Patil N, Tihan T, Cioffi G et al. Brain and other central nervous system tumor statistics, 2021. *CA Cancer J Clin.* 2021; 71(5): 381-406. doi: 10.3322/caac.21693. Epub 2021 Aug 24.
- Hirtz A, Rech F, Dubois-Pot-Schneider H, Dumond H. Astrocytoma: a hormone-sensitive tumor? *Int J Mol Sci.* 2020; 21(23): 9114. doi: 10.3390/ijms21239114.
- Yang W, Warrington NM, Taylor SJ, Whitmire P, Carrasco E, Singleton KW et al. Sex differences in GBM revealed by analysis of patient imaging, transcriptome, and survival data. *Sci Translat Med.* 2019; 11(473): eaao5253. doi: 10.1126/scitranslmed.aao5253.
- Kapoor M, Gupta V. Astrocytoma. In: StatPearls [Internet]. StatPearls Publishing; 2021. Medicine, MacDonald T, Packer RJ. Pediatric Astrocytoma.
- Neradil J, Veselska R. Nestin as a marker of cancer stem cells. *Cancer Sci.* 2015; 106(7): 803-11. doi: 10.1111/cas.12691. Epub 2015 May 26.
- Bernal A, Arranz L. Nestin-expressing progenitor cells: function, identity and therapeutic implications. *Cell Mol Life Sci.* 2018; 75(12): 2177-95. doi: 10.1007/s00018-018-2794-z. Epub 2018 Mar 14.
- Yamagishi A, Susaki M, Takano Y, Mizusawa M, Mishima M, Iijima M et al. The structural function of Nestin in cell body softening is correlated with cancer cell metastasis. *Int J Biol Sci.* 2019; 15(7): 1546-56. doi: 10.7150/ijbs.33423.
- Andrés-Sánchez N, Fisher D, Krasinska L. Physiological functions and roles in cancer of the proliferation marker Ki-67. *J Cell Sci.* 2022; 135(11): jcs258932. doi: 10.1242/jcs.258932. Epub 2022 Jun 8.
- Cidado J, Wong HY, Rosen DM, Cimino-Mathews A, Garay JP, Fessler AG et al. Ki-67 is required for maintenance of cancer stem cells but not cell proliferation. *Oncotarget.* 2016; 7(5): 6281-93. doi: 10.18632/oncotarget.7057.
- Menon SS, Guruvayoorappan C, Sakthivel KM, Rasmi RR. Ki-67 protein as a tumour proliferation marker. *Clin Chim Acta.* 2019; 491: 39-45. doi: 10.1016/j.cca.2019.01.011.
- Abdelkareem RM, Elnashar AT, Fadle KN, Muhammad EM. Immunohistochemical expression of Nestin as cancer stem cell marker in gliomas. *J Neurol Neurol Disord.* 2019; 5(1): 047-051. doi: 10.17352/jnnsd.000033.
- Bolly HM, Faried A, Hermanto Y, Lubis BP, Tjahjono FP, Hernowo BS et al. Analysis of mutant isocitrate dehydrogenase 1 immunoeexpression, Ki-67 and programmed death ligand 1 in diffuse astrocytic tumours: study of single center in Bandung, Indonesia. *J Korean Neurosurg Soc.* 2021; 64(1): 100-109. doi: 10.3340/jkns.2020.0071.
- Woo CG. Clinicopathological Significance of

- Nestin Expression as a Diagnostic and Prognostic Marker in Brain Gliomas, Independent of IDH Mutation. Research Square. 2021; 1-10. doi: 10.21203/re.3.re-994741/v1.
17. An S, Song IH, Woo CG. Diagnostic Value of Nestin Expression in Adult Gliomas. *Int J Surg Pathol.* 2023; 31(6): 1014-20. doi: 10.1177/10668969221125792. Epub 2022 Sep 27.
 18. Rehfeld M, Matschke J, Hagel C, Willenborg K, Glatzel M, Bernreuther C. Differential expression of stem cell markers in proliferating cells in glioma. *J Cancer Res Clin Oncol.* 2021; 147(10): 2969-82. doi: 10.1007/s00432-021-03704-5.
 19. Rushing EJ, Sandberg GD, Horkayne-Szakaly I. High-grade astrocytomas show increased Nestin and Wilms's tumor gene (WT1) protein expression. *Int J Surg Pathol.* 2010; 18(4): 255-9. doi: 10.1177/1066896909338596. Epub 2009 Jul 3.
 20. Dahlrot RH, Hansen S, Schroeder HD, Jensen SS, Hjelmberg J, Kristensen BW. P04.09: The Prognostic Potential Of Cd133 And Nestin In A Population-Based Cohort Of Glioma Patients. *Neuro Oncol.* 2014; 16(Suppl 2): ii38. doi: 10.1093/neuonc/nou174.141.
 21. Hatanpaa KJ, Hu T, Vemireddy V, Foong C, Raisanen JM, Oliver D et al. High expression of the stem cell marker nestin is an adverse prognostic factor in WHO grade II–III astrocytomas and oligoastrocytomas. *J Neuro Oncol.* 2014; 117(1): 183-9. doi: 10.1007/s11060-014-1376-7.
 22. Muslim LM, Hasan MM, Dosh ZN, Altoraishi KM. Immunohistochemical Study of P53 and Ki-67 in Astrocytoma. *Ann Roman Soc Cell Biol.* 2021; 25(1): 6507-25.
 23. Eneström S, Vavruch L, Frånlund B, Nordenskjöld B. Ki-67 antigen expression as a prognostic factor in primary and recurrent astrocytomas. *Neuro Chirurgie.* 1998; 44(1): 25-30.
 24. Torp SH. Diagnostic and prognostic role of Ki67 immunostaining in human astrocytomas using four different antibodies. *Clin Neuropathol.* 2002; 21(6): 252-7.
 25. Das B, Raj KV, Atla B. Clinicohistopathological study of astrocytomas along with Ki-67 proliferative index. *Int J Res Med Sci.* 2018; 6(6): 665-70.
 26. Dahlrot RH, Bangsø JA, Petersen JK, Rosager AM, Sørensen MD, Reifenberger G et al. Prognostic role of Ki-67 in glioblastomas excluding contribution from non-neoplastic cells. *Scientif Reports.* 2021; 11(1): 1-9.
 27. Shivaprasad NV, Satish S, Ravishankar S, Vimalambike MG. Ki-67 immunostaining in astrocytomas: Association with histopathological grade—A South Indian study. *J Neurosci Rural Pract.* 2016; 7(4): 510-514. doi: 10.4103/0976-3147.188626.

