

Foreign Bodies in Ear - Its Type, Diagnosis and Management

Muhammad Rafique, Arsalan Ahmed Shaikh, Atif Hafeez Siddiqui

ABSTRACT

OBJECTIVES: To evaluate the presentation, nature and fate of aural foreign bodies.

STUDY DESIGN: Descriptive Study.

SETTING: E.N.T. and Head & Neck Surgery department, Liaquat University Hospital Hyderabad from June 2014 to May 2015.

METHODOLOGY: A prospective study of 224 patients who presented with different aural foreign bodies. All patients having suspected history of aural foreign body and whom who haven't history but during examination foreign body present in ear are included in the study. The patient of all age group of both the genders was enrolled. All the data was collected on a pre-designed Performa. Statistical analysis was carried out using SPSS 16.

RESULTS: Out of 224 cases of aural foreign bodies, 50.4% were less than seven years of age, with male outnumber female. 93.3% of patients were having foreign body in one ear and 6.7% have foreign body in both ears respectively. Majority of aural foreign bodies were Beads and pearls that were seen in 30.4%. Most of the cases (87.5%) did not develop any complication during extraction. The complications observed were canal abrasion in 11 (4.9%) patients, otitis externa in 12 (5.3%) and tympanic membrane perforation in 02 (0.8%) patients.

CONCLUSION: Aural foreign bodies are commonly encountered during otorhinological practice. Various varieties of aural foreign bodies are prevalent at different parts of the world. These cases should be removed under good magnification and illumination and/or sedation/general anesthesia if needed for prevention of complication.

KEY WORDS: Foreign bodies, general Anesthesia, tympanic membrane perforation.

This article may be cited as: Rafique M, Shaikh AA, Siddiqui AH. Foreign Bodies in Ear - Its Type, Diagnosis and Management. J Liaquat Uni Med Health Sci. 2015;14(02):86-9.

INTRODUCTION

An aural foreign body is commonly seen during otolaryngology practice. The self insertion of foreign bodies has been acknowledged to be a common presentation in children and psychologically disturbed patients. Common aural foreign objects include rubber, erasers, pebbles, beads, safety pins, sponges, and chalk etc¹.

Aural foreign bodies found in all age groups and both gender. This condition is frequently seen more in school going children than the infants. Foreign bodies extract from external auditory canal is routine procedure performed in E.N.T. department. Removal of foreign body is not a simple procedure but it need general anesthesia with the help of microscope and especially designed instrument, so maintaining the integrity of normal anatomy and physiology of external ear². Aural foreign body extraction was difficult and challenging procedure because of the delicate structure, complex anatomy, variety of foreign body and experience of the consulting surgeon³.

Aural foreign bodies are classified in different categories i.e. living or non living, metallic – nonmetallic, rounded or multi dimension, soft, firm or hard, and so forth, according to their nature⁴. The pathophysiology

of aural foreign bodies has been recognized to general curiosity of the children to insert object while playing in home or outside the home into different orifices of the body like ear, nose etc. Those patient suffering from the ear diseases causing irritation develops regular cleaning habit and therefore prone to accidental entry of foreign body in ear commonly ear buds etc.⁵. The purpose of study is to describe the spectrum of the nature of the foreign bodies in this part of the world and outcome of foreign bodies in ear at our institution.

MATERIALS AND METHODS

This is a descriptive study carried out in the department of ENT – Head & Neck Surgery, Liaquat University Hospital, Hyderabad (Sindh). The duration of study is one years, from June 2014 to May 2015. A prospective study involving 224 patients presented with different varieties of aural foreign bodies. History and patients data included age, sex and presenting symptoms had been taken as well as complete ENT examination was performed. All patients having suspected history of aural foreign body and whom who haven't history but during examination foreign body present in ear are included in the study. Those

Patients who tried to remove their foreign body in other hospital or those foreign bodies who cause complications were excluded from this study. The use of aural syringing, vacuum suction, and manual instrumentation by the use of Jobson Horne's probe or hook and crocodile forceps may be indicated. General anesthesia used; mostly in children; only in cases of poor cooperation, deeply impacted foreign body and mentally retarded patients. After extraction of foreign body, re-examination of the affected ear was performed immediately and after three days to exclude the possible complications. General anesthesia used; mostly in children; only in cases of poor cooperation, deeply impacted foreign body and mentally retarded patients. After extraction of foreign body, re-examination of the affected ear was performed immediately and after three days to exclude the possible complications.

All data was recorded and entered in especially designed proforma and analysed using SPSS V.16. The data included age, gender, laterality, mode of presentation, duration of foreign body retained, nature of the foreign body, method of removal and the development of any complications. Finally the results were deduced and presented in the form of frequencies and proportions.

RESULTS

This study includes 224 patients which having with foreign body in ear. Out of these 165 (73.6%) were male and 59 (26.4%) were female and male to female ratio was 2.8:1 (Figure I). The mean age was 19 (± 2.1) years, ranged from one year to above 60 years old. 50.4% (113) of the cases were less than seven years of age.

Among 224 patients of foreign bodies, 209 (93.3%) of patients present unilaterally while 15 (6.7%) of patients present bilaterally. one hundred and ten (49.1%) patients had foreign bodies in right ear, 99 (44.2%) patients in left ear (Table I).

Most common types of foreign bodies were Beads and pearls that were seen in 68 patients (30.4%), cotton tips and match stick were extracted from 50 patients (22.3%), vegetable seeds were extracted from 31 patients (13.8%), Papers and Rubber were extracted from 27 patients (12.1%), insects were extracted from 24 patients (10.7%), button batteries were extracted from 13 patients (5.8%), and stone and Arica nut (Chilia) were extracted from 7 patients (3.1%) respectively (Table II).

Most of the cases did not develop complications 199 (89%) during extraction (Table III). The main complications were canal abrasion 11 (4.9%) patients, otitis externa in 12 (5.3%) and tympanic membrane perforation in 02 (0.8%) patients (Figure II).

FIGURE I: GENDER DISTRIBUTION (n=224)

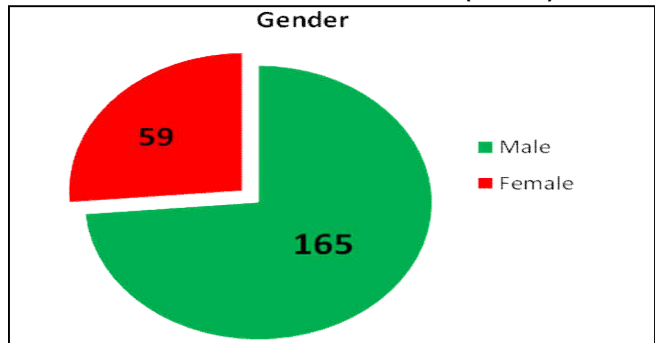


TABLE I: SITE DISTRIBUTION OF FOREIGN BODY (n=224)

Site	Number	Percentage
Bilateral	15	6.7%
Unilateral	209	93.3%
1 à Right ear	110	49.1%
2 à Left ear	99	44.2%

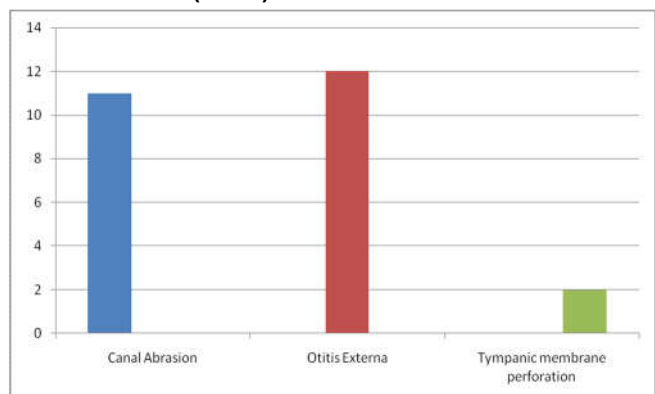
TABLE II: TYPE OF FOREIGN BODY IN EAR (n=224)

Type	Number	Percentage
Beads & Pearls	68	30.4%
Cotton bud & Match sticks	50	22.3%
Vegetable seeds	31	13.8%
Paper & Rubber	27	12.1%
Insects	24	10.7%
Button batteries	13	5.8%
Stone and Erica nut	07	3.1%

TABLE III: FREQUENCY OF COMPLICATION (n=224)

Complication	Number	Percentage
No	199	89%
Yes	25	11%

FIGURE II: TYPE OF COMPLICATIONS DURING EXTRACTION (n=25)



DISCUSSION

Otological foreign bodies are common across the ages, it happens in both the children and adult and especially mentally retarded patients. There were numerous of studies conducted in different part of world for looking the prevalence, diagnosis, treatment and complication of different kind of foreign bodies.

In young children the usual site of foreign body insertion is ear. Non-living aural foreign bodies may include cotton wool, bean, bead, paper/plastic, eraser, insect, paddy seed, and popcorn kernel etc⁶. The patients usually come with the history of pain in the ear and sense of heaviness in the ear and some time discharge from the ear. Majority of the patient don't have any complaint but foreign body found in ear during routine ear examination. Examination under anesthesia with an operating microscope helps to confirm the presence of aural foreign bodies; it also helps in retrieval of foreign body. It is beneficial in patients who do not allow removal of foreign body without anesthesia⁷.

Male preponderance (73.6%) in this study is in agreement with finding of the others. An international study reported 52% male and 48 % female patients⁸. Shrestha I et al also reported that male are affected more than the female⁹. However one study has reported the increased frequency in female¹⁰.

In our study 50.4% of the cases were less than seven years of age, a finding consistent with other international studies^{11, 12}. Chai et al, studied 480 cases of ear foreign body. They reported highest percentage (48.3%) of aural foreign bodies in less than five years; followed by children between 6 and 10 years¹³.

In this research we found that the majority of foreign bodies in ear were Beads and pearls that were seen in 30.4%, cotton tips and match stick were 22.3%, vegetable seeds were 13.8%, papers were 12.1%, insects were 10.7%, button batteries were 5.8%, and stone and Arica nut (Chilia) were 3.1% patients respectively. There were wide variations regarding the type of the aural FB; in western study, seeds or nuts were the commonest ear foreign bodies encountered which consisted of 47.1% cases; this was followed by plastic toys or beads¹³. In other international study reported that the grains and seeds 27.9%, beads 19.7%, cotton wool 13.6%, paper 8.8%, and eraser 8.2% formed the bulk of the aural foreign body⁴, but this differed from our results in which beads and cotton tips were common as compared to seeds; this was consistent with other studies¹⁴. In other study, garlic was encountered as an animate FB because it was used traditionally for the relief of earache¹⁵.

A very interesting foreign body reported in an international study that the different types of blue tooth devices extracted from the external auditory canal. Blue-tooth device objects were small pieces of magnetic property used with the aid of mobile that communicate with the far distance. This metallic piece was introduced through the ear canal and applied in contact with the tympanic membrane and that different range of it¹⁵.

Complication due to presence of foreign body or during extraction was uncommon. In this study 89% patients do not developed any complication during extraction. The complications (11%) noticed were canal abrasion 4.9% patients, otitis externa in 5.3% and tympanic membrane perforation in 0.8% of patients. This is in sharp contrast to study of Singh et al who reported 77% complication rate¹⁶. A probable explanation for this contrast finding could be that all patients in our study underwent elective removal of the foreign body; whose shape, type and site found likely to cause trauma during removal; instead of removal in emergency or outdoor patient department setting¹⁷. Moreover proper position of the patient and selection of appropriate instrument (s) helps in easy removal of aural foreign bodies in patients especially children¹⁷.

We observed that the rate of complications is high after removal of sharp and multi dimension foreign bodies. In contrast rounded or soft foreign bodies had high success rate of removal under direct visualization. The foreign bodies completely occluding the external auditory canal or those stuck up near the tympanic membrane may be removed by special designed hock; yet the removal is associated with complication.

CONCLUSION

Aural foreign bodies are prevalent in all parts of the worlds; when removed under good magnification and illumination and/or sedation/general anesthesia carries minimum rate of complications.

REFERENCES

1. Parajuli R. Foreign bodies in the ear, nose and throat: an experience in a tertiary care hospital in central Nepal. *Int Arch Otorhinolaryngol*. 2015; 19 (2):121-3.
2. Mangussi-Gomes J, Andrade JS, Matos RC, Kosugi EM, Penido Nde O. ENT foreign bodies: profile of the cases seen at a tertiary hospital emergency care unit. *Braz J Otorhinolaryngol*. 2013 Nov-Dec;79(6):699-703
3. Ibekwe M, Onotai L, Otaigbe B. Foreign body in the ear, nose and throat in children: a five year

- review in Niger delta. African Journal of Paediatric Surgery. 2012;9(1):3-7.
4. Ologe FE, Dunmade AD, Afolabi OA. Aural foreign bodies in children. Indian J Pediatr. 2007;74(8):755-758.
 5. Kroukamp GR, Loock JW. Foreign bodies in the ear. In: Gleeson M, Browning GG, Burton MJ, et al., editors. Scott-Brown's Otorhinolaryngology, Head and Neck Surgery. 7th edition. Vol. 3. New York, NY, USA: Hodder Arnold; 2008. pp. 3370-3372.
 6. Heim SW, Maughan KL. Foreign bodies in the ear, nose, and throat. Am Fam Physician. 2007; 15:76(8):1185-1189.
 7. Williams J, Mirza A, To K, Tzifa K, McClelland L, Daniel M. Removal of foreign bodies from children's ears: a nurse-led clinic. Nurs Stand. 2013; 21-27;27(51):43-6.
 8. Ray R, Dutta M, Mukherjee M, Gayen GC. Foreign body in ear, nose and throat: experience in a tertiary hospital. Indian J Otolaryngol Head Neck Surg. 2014;66(1):13-6.
 9. Shrestha I, Shrestha BL, Amatya RC. Analysis of ear, nose and throat foreign bodies in Dhulikhel hospital. Kathmandu Univ Med J (KUMJ) 2012;10 (38):4-8.
 10. Shafi M, Yousufani AH, Hussain SI. Foreign Bodies in External Auditory Canals: Experience of 653 Cases Over 8 Years. JLUMHS. 2010;09(02):70-75.
 11. Olajide TG, Ologe FE, Arigbede OO. Management of foreign bodies in the ear: a retrospective review of 123 cases in Nigeria. Ear, Nose and Throat J. 2011; 90(11):E16-9.
 12. Wada I, Kase Y, Iinuma T. Statistical study on the case of aural foreign bodies. Nihon Jibiinkoka Gakkai Kaiho (Journal of Otolaryngology of Japan). 2003;106(6):678-684.
 13. Chai CK, Tang IP, Tan TY, Jong DE. Review of ear, nose and throat foreign bodies in Sarawak General Hospital. A five year experience. Med J Malaysia. 2012; 67(1): 17-20.
 14. Ryan C, Ghosh A, Wilson-Boyd B, O'Leary S. presentation and management of aural foreign bodies in two Australian emergency departments. Emerg Med Australas. 2006; 18(4): 372-8.
 15. Al-Juboori AN. Aural foreign bodies: descriptive study of 224 patients in Al-Fallujah general hospital, Iraq. Int J Otolaryngol. 2013; 2013: 401289.
 16. Singh GB, Sidhu TS, Sharma A, Dhawan R, Jha SK, Singh N. Management of aural foreign body: an evaluative study in 738 consecutive cases. Am J Otolaryngol. 2007;28(2):87-90.
 17. Ali Z, Bashir F, Naqi SA. Frequency of complication in Aural foreign Bodies. J. Med. Sci. 2013;21 (4):177-179.



AUTHOR AFFILIATION:

Dr. Muhammad Rafique (Corresponding Author)

Associate Professor, Department of ENT
Liaquat University of Medical & Health Sciences
(LUMHS), Jamshoro, Sindh-Pakistan.
Email: rafique.kaimkhani@gmail.com

Dr. Arsalan Ahmed Shaikh

Assistant Professor, Department of ENT
LUMHS, Jamshoro, Sindh-Pakistan.

Dr. Atif Hafeez Siddiqui

Assistant Professor, Department of ENT
Dow University of Health Sciences Karachi, Sindh-Pakistan.