

## Case Report

# Maxillary Adenomatoid Odontogenic Tumour - An Uncommon Oral Pathology, Reported Locally

Shahjahan Katpar, Mehwash Kashif, Naghma Azad, Navid Rashid Qureshi

### ABSTRACT

**BACKGROUND:** Adenomatoid odontogenic tumor (AOT) is relatively an uncommon oral tumour, which accounts for about 3-7% of all odontogenic tumors as reported in the literature, but local reporting in Pakistan is insignificant. AOT is a benign (hamartomatous), noninvasive odontogenic tumour with slow and sustained growth. This report describes the surgical therapy, clinical course and morphological characteristics of an AOT, which developed in the maxilla of 22 years old female patient, initially diagnosed as a Globulomaxillary Cyst, based on the clinical and radiological features. No local recurrence has been observed so far, as it was successfully completely removed under local anaesthesia.

**KEY WORDS:** Adenomatoid odontogenic tumor, Globulomaxillary Cyst, Maxilla, local anaesthesia, Pakistan.

### INTRODUCTION

Adenomatoid odontogenic tumor (AOT) is an uncommon tumor of odontogenic origin, with a relative frequency of 2.2 – 7.1%.<sup>1</sup> It comes in a variety of histoarchitectural patterns, and characterized by its slow but progressive growth.<sup>2</sup> AOT is a rare odontogenic tumor, which is usually associated with unerupted teeth or dentigerous cysts<sup>3</sup>. Regarding its pathogenesis, the lesion originates from odontogenic epithelium (enamel organ or dental lamina remnants) with inductive influence on odontogenic ectomesenchyme and consequent production of dentinoid material.<sup>4</sup> Radiographically, the tumour usually appears as a well circumscribed, unilocular radiolucency, which may be associated with an unerupted tooth, most often a canine.<sup>5</sup>

Topographically, the AOT occurs in peripheral and central variants, the latter type is further divided into follicular (with embedded tooth) and extra-follicular (without an embedded tooth) types. The central variant accounts for 97.2%, and from which 73.0% of its types are follicular. The follicular variant (M: F ratio 1 to 1.9) is three times as frequent as the extra-follicular type. The follicular variant is diagnosed earlier in life (mean age 17 yr) than the extra-follicular type (mean age 24 yr); 53.1% of all variants occur within the teen years (13–19 yr). A study showed that follicular AOT was associated with one embedded tooth in 93.2%. Maxillary permanent canines account for 41.7% and all four canines for 60.1% of AOT-associated embedded teeth.<sup>6</sup>

The follicular variant of AOT is thought to be originated from the reduced enamel epithelium of the dental follicle. The origin of extra follicular remnants remains less clear. The available evidence seems to

indicate that some extra follicular AOTs might arise as secondary phenomenon within the pre-existing odontogenic cysts or cystic tumors.<sup>7</sup>

We have not been able to find any local reference of AOT in Pakistani literature and feel that it may be surgically removed by many surgeons but is not being documented and has an insignificant contribution. Therefore, this paper is being presented as a stepping stone for Pakistan's local maxillofacial literature.

### CASE REPORT

A 22 years old female patient was referred from the Department of Oral Medicine with the complaint of painful swelling present in the right maxillary canine region since last two months, for further investigations, diagnosis and management, to the Department of Oral and Maxillofacial Surgery at Dr. Ishratul-Ibad- Institute of Oral Health Sciences (former Sind Medical College Campus building), Dow University of Health Sciences in November 2008. Patient's history revealed that, the swelling had gradually increased in size causing discomfort in the affected region. Her past medical and dental history was not significant. On clinical intraoral examination we revealed a firm, rounded and tender swelling, present in the right maxillary region, which was extending from distal surface of maxillary right lateral incisor to the distal surface of maxillary right canine tooth (**Figure 1**). On palpation the swelling was firm, tender, smooth surfaced, non fluctuant and non compressible. The respected teeth associated with the swelling were all intact, however upper right central incisor tooth was in slight supra-occlusion and tilted palatally.

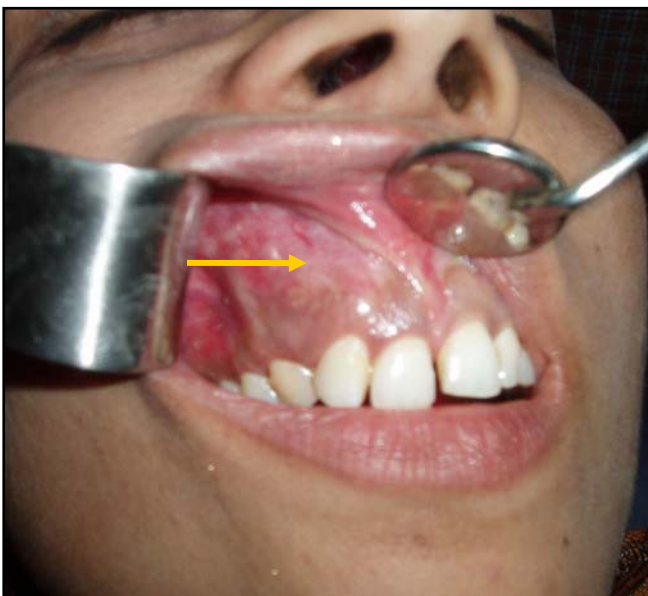Patient's panoramic (OPG) examination showed a pear shaped well defined radiolucent area causing

bone resorption, present between the diverging roots of right maxillary central incisor and first premolar tooth with no evidence of root resorption (**Figure II**). She had also associated bilateral horizontal mandibular impacted wisdom teeth, without any obvious complaints.

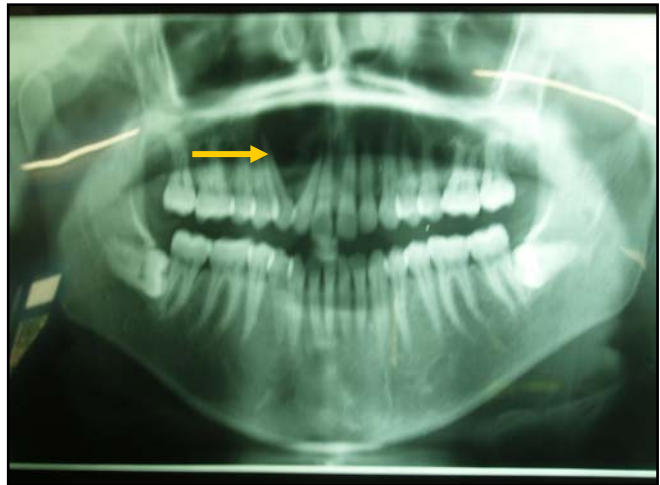
Based on the clinical and radiological OPG x-ray findings, provisional diagnosis of Globulomaxillary cyst maxilla was made and an elective surgical enucleation procedure was planned under local anaesthesia. Routine preoperative work was done and after informed consent enucleation of the suspected cystic pathology was done. A full thickness mucoperiosteal flap was raised extending from right maxillary central incisor up to the right maxillary first premolar tooth (**Figure III**). The small existing bony window was enlarged and the lesion was successfully enucleated as a whole in-toto (**Figure IV**).

The histopathological findings revealed a benign encapsulated mass composed of whorls, sheets and strands of epithelial cells, along with microcysts and ducts lined by cuboidal to tall columnar cells. The microcysts contain an eosinophilic material. Foci of an amorphous material was also seen among the sheets of epithelial cells. Areas of hemorrhage, dilated and congested blood vessels were also noted. It was diagnosed as an Adenomatoid odontogenic tumor (**Figure V**). The healing was uneventful and fortunately follow up visits were not associated with any postoperative complications.

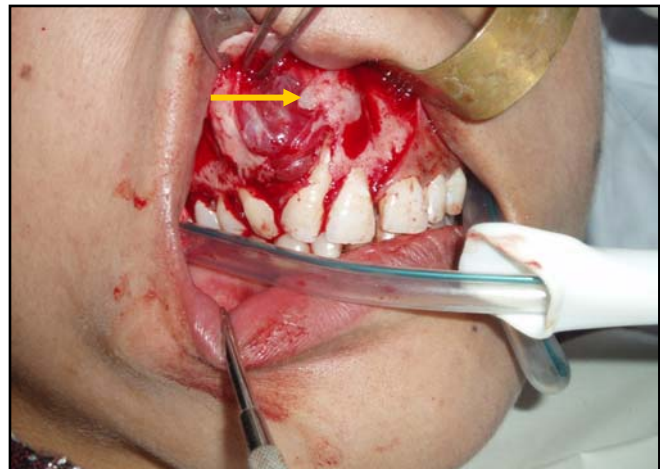
**FIGURE I: CLINICAL PHOTOGRAPH: ARROW SHOWING SWELLING IN THE CANINE RIGHT MAXILLARY AREA**



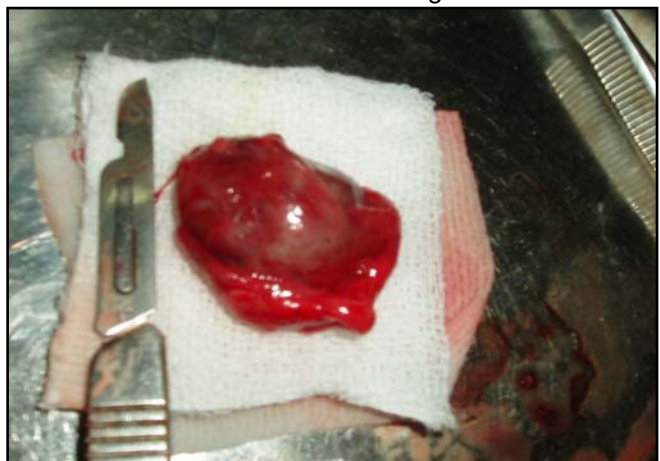
**FIGURE II: OPG RADIOGRAPH-ARROW SHOWING WELL DEFINED RADIOLUCENCY IN THE RIGHT MAXILLARY CANINE REGION**



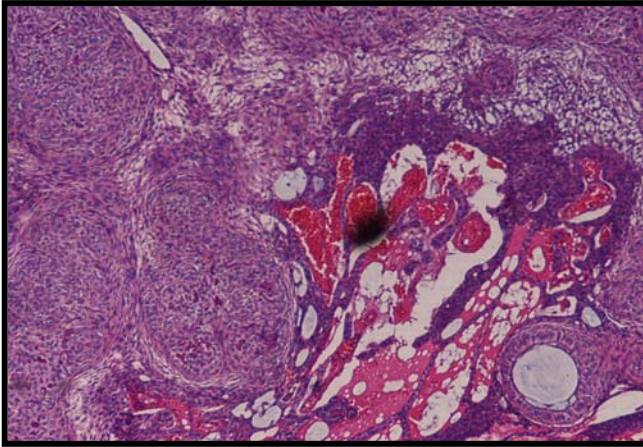
**FIGURE III: INTRA-OPERATIVE CLINICAL PHOTOGRAPH (ARROW) SHOWING PATHOLOGICAL LESION**



**FIGURE IV: THE PATHOLOGICAL LESION ENUCLEATED IN TOTO measuring 3.0x2.0x1.5cms**



**FIGURE V:  
H&E STAIN, 10X10 MAGNIFICATION, HYPERCEL-  
LULAR AOT TUMOR WITH EPITHELIAL PROLIF-  
ERATION CONSISTS OF SMALL POLYHEDRAL  
CELLS WITH LITTLE CYTOPLASM ARRANGED IN  
STRANDS, SHEETS AND WHORLED AREAS**



## DISCUSSION

This case of AOT was not on our list of differential diagnosis as it seemed to fit the features of Globulomaxillary cyst due to its clinical and radiological presentation, which was finally diagnosed as an AOT after its total surgical removal as a chair-side procedure and the histopathology report revealed it as AOT. We have also searched our local literature but could not be able to find any local references on AOTs in Pakistan, therefore, this case is being documented to share our clinical experience, which will also increase our local Maxillofacial literature bank.

Adenomatoid odontogenic tumor (AOT) is a relatively uncommon distinct odontogenic neoplasm that was first described by Steensland in 1905.<sup>8</sup> However, variety of terms has been used to describe this tumor. Unal et al produced a list containing all nomenclatures for AOT reported in the literatures. Many different names like adenoameloblastoma, ameloblastic adenomatoid tumor, adamantinoma, epithelioma adamantinum or teratomatous odontoma have been used in the past to define the lesion, but currently it is called as, AOT.<sup>9</sup>

From the early 1990s onwards 65 single cases of AOT (excluding case series of more than 10 cases) have been published. Age distribution shows that more than two-third are diagnosed in the second decade of life and more than half of the cases occur within the teens (13-19 years of age). The female: male ratio for all age groups and AOT variants together is 1.9:1. The marked female predominance (around 3:1) among certain Asian population needs further clarification.<sup>10</sup> The AOT was predominantly found in the upper jaw

(maxilla: mandible = 2.6: 1).<sup>11</sup>

Clinical features generally focus on complaints regarding a missing tooth. The lesion usually present as asymptomatic swelling, which is slow growing and often associated with an unerupted tooth. However, the rare peripheral variant occurs primarily in the gingival tissue of tooth-bearing areas<sup>11</sup>. Unerupted permanent canine are the teeth most often involved with AOTs.

The radiographic findings of AOT frequently resemble other odontogenic lesions such as dentigerous cysts, calcifying odontogenic cysts, calcifying odontogenic tumors, globule-maxillary cysts, ameloblastomas, odontogenic keratocysts and periapical disease.<sup>12</sup> Whereas the follicular variant shows a well-circumscribed unilocular radiolucency associated with the crown and often part of the root of an unerupted tooth, the radiolucency of the extra-follicular type is located between, above or superimposed upon the roots of erupted permanent teeth.<sup>3</sup> Displacement of neighboring teeth due to tumor expansion is much more common than root resorptions. The peripheral lesions may show some erosions of the adjacent cortical bone.<sup>6</sup>

Remarkably, all variants of AOT show identical histology. The histological typing of the WHO defined the AOT as a tumor of odontogenic epithelium with duct-like structures and with varying degrees of inductive changes in the connective tissue. The tumor may be partly cystic, and in some cases the solid lesion may be present only as masses in the wall of a large cyst.<sup>13</sup> Moreover, eosinophilic, uncalcified, amorphous material can be found and is called "tumor droplets". Some tumor droplets show a homogenous matrix whereas most tumor droplets reveal electron-dense plaques,<sup>14</sup> most probably represent some form of enamel matrix.<sup>10</sup> Conservative surgical enucleation is the treatment modality of choice. Recurrence of AOT is exceptionally rare. Only three cases in Japanese patients are reported in which the recurrence of this tumor occurred<sup>15</sup>, therefore, the prognosis is excellent when completely removed in toto.

## CONCLUSION

AOT is an uncommon odontogenic lesion, seen primarily in the adolescence females. This report describes a rare entity of extra-follicular type of AOT in Pakistani population, most probably the first of its type, which was successfully removed under local anesthesia in toto. There is an important need to report similar and other such cases, as we feel that many cases are surgically managed but unfortunately not reported. All such cases should be reported by the maxillofacial clinicians, so that we can increase not only our local literature bank, but also play a posi-

tive contribution to our expanding and demanding maxillofacial specialty.

#### ACKNOWLEDGEMENT

We would like to acknowledge Dr. Saleem Khanzada (DDRL-DUHS) for Reporting and helping us in the histopathology and Dr. Radiha Alvi, Dr Faiza Malik, Dr Sanober Naz the house surgeons posted in the Department of Oral Surgery for their help in this case.

#### REFERENCES

1. Garg D, Palaskar S, Shetty VP, Bhushan A. Adenomatoid odontogenic Tumor- Hamartoma or True neoplasm: a case report. *J Oral Sci.* 2009;51(1):155-9.
2. Xiang C, Yan. Adenomatoid odontogenic tumor: a report of a rare case with recurrence. *J Oral Path Med.* 2007;36(7):440-3.
3. Blumenthal MN, Mostofi R. Repair of an intrabony defect from an adenomatoid odontogenic tumor. *J Periodontol.* 2000;71(10):1637-40.
4. Neville BW, Damm DD, Allen CM, Bouquot JE, editors. *Oral and maxillofacial pathology.* 2<sup>nd</sup> edition. Philadelphia: WB Saunders; 2002. p.621-23.
5. Ali K, Munir FM, Nazir A. Clinical presentation and management of adenomatoid odontogenic tumour. *Pak Oral Dnt J.* 2006;26(2):163-5.
6. Philipsen HP, Reichart PA, Zhang KH. Adenomatoid odontogenic tumor: biologic profile based on 499 cases. *J Oral Path Med.* 2009;20(4):149-58.
7. Jivan V, Altini M, Meer S, Mahmood F. Adenomatoid odontogenic tumor originating in a Unicystic ameloblastoma: a case report. *Head Neck Path.* 2007;1(2):146-9.
8. Steensland HS. Epithelioma adamantinum. *J Exper Med.* 1905;6:377-89.
9. Unal T, Cetingul E, Gunbay T: Peripheral adenomatoid odontogenic tumor: Birth of a term. *J Clin Pediatr Dent.* 1995;19:139-42.
10. Philipsen HP, Reichart P A. Adenomatoid odontogenic tumour: facts and figures. *Oral Oncol.* 1999;35(2):125-31.
11. Buchner A, Sciubba JJ. Peripheral odontogenic tumours: a review. *Oral Surg Oral Med Oral Pathol* 1987;63:688-97.
12. Konouchi H, Asaumi J, Yanagi Y, Hisatomi M, Kishi K. Adenomatoid odontogenic tumor: correlation of MRI with histopathological findings. *Eur J Rad.* 2002;44:19-23.
13. Handschel GJK, Depprich RA, Zimmermann AC, Braunstein S, Kübler NR. Adenomatoid odontogenic tumor of the mandible: review of the literature and report of a rare case. *Head Face Med.* 2005;1:3.
14. Philipsen HP, Reichart PA: The adenomatoid odontogenic tumour: ultra structure of tumour cells and non-calcified amorphous masses. *J Oral Pathol Med.* 1996;25:491-96.
15. Philipsen HP, Reichart PA, Nikai H. The adenomatoid odontogenic tumour (AOT): an update. *Oral Med Path.* 1997;2:55-60.



#### AUTHOR AFFILIATION:

**Dr. Shahjahan Katpar** (*Corresponding Author*)

Head of Dental College & Vice Principal  
Bahria University Medical & Dental College Karachi, Sindh-Pakistan.  
Email : sj\_katpar@yahoo.com

**Dr. Mehwash Kashif**

BDS, FCPS-II Resident, Oral Surgery  
Liaquat College of Medicine and Dentistry Karachi, Sindh-Pakistan.

**Dr. Nagma Azad**

Senior Registrar and HOD Oral Medicine & Diagnosis  
Dr. Ishrat-ul-Ebad Institute of Oral Health Sciences  
Dow University of Health Sciences Karachi, Sindh-Pakistan.

**Prof. Navid Rashid Qureshi**

Principal & Head of Department Oral & Maxillofacial Surgery  
Liaquat College of Medicine and Dentistry Karachi, Sindh-Pakistan.