

# Stroke Localization: Clinical Correlation versus Findings of CT Scan Brain in Patients Admitted at Liaquat University Hospital Hyderabad/Jamshoro

Ghulam Hussain Baloch, Samiullah Shaikh, Mukhtiar Hussain Jaffery, Suhail Ahmed Almani, Noor Muhammad Memon and Muhammad Qasim

## ABSTRACT

**OBJECTIVE:** To study clinical localization of stroke and correlate with findings on C-T Scan of brain.

**DESIGN:** Observational study.

**PLACE AND DURATION OF STUDY:** The study was conducted at the Medical Department of Liaquat University Hospital Hyderabad/Jamshoro from January 2006 to December 2006.

**MATERIAL AND METHODS:** Total 110 patients with features of stroke were included in this study. These patients were further evaluated for clinical correlation with findings on CT scan brain, done within 24 hours after the development of focal neurological deficit. Brain tumor, meningitis, viral or bacterial encephalitis, multiple sclerosis and metabolic derangements that could explain focal neurological deficit e.g hypoglycemia were the exclusion parameters.

**RESULTS:** Total of 110 patients, 60 (54.5%) were males and 50 (45.5%) were females. Age of patients ranged 22-84 years with mean±SD age of 53±5 years. On clinical ground cerebral infarction was suspected in 89 (80.9%) and cerebral hemorrhage in 21 (19.1%) patients. In 74 (83%) patients infarction was confirmed by CT scan brain, whereas cerebral hemorrhage was proved in 10 (47.6%) out of a total of 21 patients. These patients were further evaluated for clinical localization of area of stroke. Clinically left parietal / temporo parietal lobe infarction was suspected in 43 patients and right parietal / temporo parietal lobe in 25 patients. Left frontal lobe infarction in 7 patients right frontal lobe infarction in 8 patients, left internal capsule infarction in 2 patients and right internal capsule infarction in 4 patients. Comparing with the CT scan brain findings: left parietal / temporo parietal lobe infarction was confirmed in 41 (95.34%) patients, right parietal / temporo parietal lobe in 19 (76%), left frontal lobe in 5 (71.4%), right frontal lobe in 4 (50%), left internal capsule in 2 (100%) and right internal capsule in 3 (75%) patients.

Left middle cerebral artery territory involvement was observed in 43 (58%) patients and right middle cerebral artery territory in 22(30%) patients. No Significant difference was observed in other cerebral artery territories.

**CONCLUSION:** It was concluded from the study that cerebral infarction was more common than hemorrhage and middle cerebral artery territory infarction of both sides was more common than other cerebral artery territories. Localization of stroke on clinical basis is not always easy. Confident diagnosis requires careful case history taking, extensive neurological assessment and with the help of focal neurological deficit of a particular area.

**CATEGORY:** Internal Medicine

**KEYWORDS:** Stroke - Ischemic strokes - Intra cerebral hemorrhage - localization.

## INTRODUCTION

Stroke is defined as 'the rapidly developing clinical symptoms and sign of focal (or global) disturbance of cerebral function with symptoms lasting for more than 24 hours or longer or leading to death with no apparent cause other than vascular origin<sup>1</sup>. Stroke ranks second after ischemic heart disease as a cause of DALY (Disability Adjusted Life in Years) in high-income countries and as a cause of death worldwide.<sup>2</sup>

Ethnic, socio-economic and dietary factors may be responsible for this variance. Retrospective analysis of patients admitted with stroke in two hospitals of the same locality some 8 years ago in Karachi, Pakistan showed that out of the 12,454 cases 796(6.4%) had stroke.<sup>3</sup> According to WHO report 2002, total mortality due to stroke in Pakistan was 78512.<sup>4</sup> The incidence of stroke varies among countries and increases exponentially with age.<sup>5</sup> It is also the leading cause of dis-

ability in adults. Among the 350,000 survivors each year, 31% require assistance in activities of daily living, 20% require assistance in walking and 16% require institutional care.<sup>6</sup> Stroke not only increases mortality but also put a great economic burden on the society.<sup>7</sup> In western societies, about 80% of strokes are caused by focal cerebral ischemia and the remaining 20% are caused by hemorrhages.<sup>5</sup> It is difficult to assess clinically about the type of stroke in the majority of patients as there is no specific differentiating feature. Computed tomography scan brain (plain) is an accurate, safe and noninvasive procedure for differentiating between cerebral infarction and hemorrhage. It also shows site of lesion. Though the mortality for stroke has been on the decline still it represents the most common cause of chronic disability. Localization of stroke on clinical basis is not always easy. With the help of focal neurological deficit for particular area we would be able to make confident diagnosis. Localization area of stroke helps in prognosis outcome, occupational and therapeutic strategies. This localization of stroke is easily done by careful history taking and extensive neurological examination. The purpose of this study was to determine clinical stroke localization in admitted patients and correlation with findings on CT scan of brain in patients hospitalized at Liaquat University Hospital Hyderabad / Jamshoro.

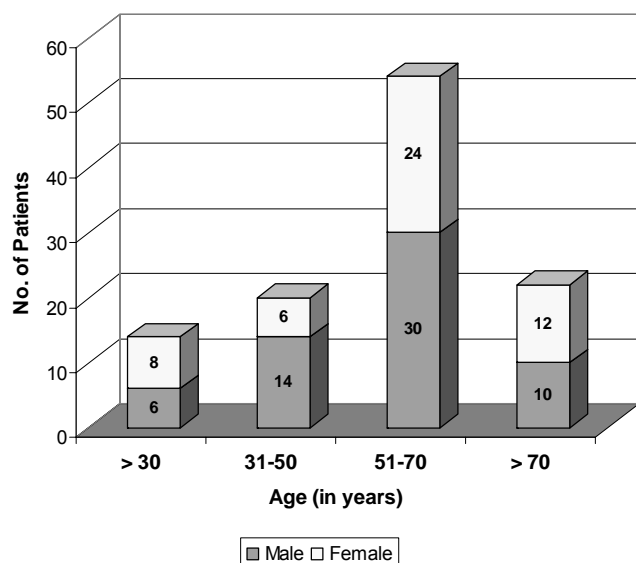
#### **METHOD AND MATERIAL**

Patients admitted to medical ward of Liaquat University Hospital Hyderabad / Jamshoro during the period of January 2006 to December 2006. This was an observational study in patients above the age of 18 years with stroke, verified by CT scan brain done within 24 hours after the development of focal neurological deficit. The area of brain involvement was assessed by clinical determination of focal neurological deficits. All these patients were further evaluated to clinically distinguish between ischemic or hemorrhagic stroke by history of unconsciousness, headache, vomiting, elevated blood pressure and other clinical neurological findings. Patients with meningitis, brain tumor, encephalitis, epilepsy, hepatic coma, history of head injury, TIA, multiple sclerosis & metabolic degenerative disorders that could explain focal neurological defect e.g. hypoglycemia were exclusion parameters. Data were analysed by SPSS V. 13.

#### **RESULTS**

Total 110 patients were evaluated, 60 (54.5%) were males & 50 (45.5%) were females. Age of patients range 22-84 years with mean age of  $53 \pm 5$  years. Stroke was found more commonly in age group of 51-70 years in 54 (49%). Patients of more than 70 years of age were 22 (20%), between 30-50 year 20 (18.2%) & under 30 year 14 (12.8%) (**Figure I**). Of these 110 patients 89 (80.9%) were diagnosed cerebral infarction on clinical ground and 21 (19.1%) patients were diagnosed cerebral hemorrhage. Area of stroke was localized clinically by presence of focal neurological signs of particular area of brain (**Table I**) and confirmed by CT scan brain done within 24 hours of development of focal neurological deficit as shown in **Table II**. Distribution of cerebral arterial territories involvement is described in **Table III**. Out of these 89 (clinically diagnosed cerebral infarctions), in 74 (83%) patients infarction was confirmed by CT scan brain, whereas in remaining 15 (17%) patients CT scan brain was normal or inconclusive. Out of 21 clinically suspected hemorrhagic stroke patients, only 10 (47.6%) were confirmed by CT scan. We further correlate the clinically diagnosed area of brain involvement with CT scan brain findings. In 43 patients left parietal lobe infarction was suspected clinically and confirmed by CT scan in 41 (95.4%) patients. Whereas in right temporo parietal lobe infarction was suspected in 25 patients, infarction was confirmed in 19 (76%) patients. Left frontal lobe infarction was suspected clinically in 07 patients and confirmed by CT scan in 05 (71.4%) patients. Right frontal lobe infarction was suspected in 08 patients confirmed by CT scan in 04 (50%) patients. In 02 patients infarction was suspected at left internal capsule and CT scan confirm area of involvement in both (100%). Whereas in 04 patients right internal capsule infarction was suspected and infarction was confirmed in 03 (75%) patient. Of 21 clinically diagnosed cerebral hemorrhages 12 were diagnosed intra lobar cerebral hemorrhage and 09 were sub arachnoid (ventricular) hemorrhage. On CT scan brain intra lobar cerebral hemorrhage in was found in 03 (30%) patients and sub arachnoid (ventricular) hemorrhage in 05 (50%) patients, in 1 (10%) case basal ganglia hemorrhage and in 1 (10%) case multiple cerebral hemorrhage (**Figure II**).

**FIGURE I:**  
Age Distribution (n=110)



with stroke was  $53 \pm 5$  year. That is compatible with study done by Jahangir et al<sup>8</sup>, and also study done by Zahir Shah at Peshawar.<sup>9</sup> He noticed in his study that mean presenting age of stroke patients was 55 years. Localization of area of infarction on the basis of clinical focal neurological deficit is not always accurate. With the help of focal neurological deficit for particular area, we were able to make confident diagnosis. This Clinical localization of stroke is best done by careful history taking and extensive neurological assessment. Localizing area of stroke helps in prognosis and outcome of stroke patients and therapeutic or occupational strategies. In our study parietal / temporo parietal lobe infarction (middle cerebral artery territory) of both side is more significant than other lobar infarction (anterior cerebral and posterior cerebral artery territories). Zahir Shah in his study observed that middle cerebral artery territory was most commonly involved<sup>9</sup>. About 80% of the patients had infarction of carotid

**TABLE I: FOCAL NEUROLOGICAL DEFECIT / CLINICAL DIAGNOSIS**

Focal Neurological Deficit	No. of Patients	Clinical Diagnosis	Focal Neurological Deficit	No. of Patients	Clinical Diagnosis
Right arm and face weakness > leg	30	Left parietal Lobe	Left arm and face weakness > leg	25	Right-Parietal/Temporo-parietal Lobe
Right arm and face weakness > leg with dysphasia	13	Left Temporo-parietal	-	-	-
Right leg weakness > arm and face	7	Left Frontal Lobe	Left leg weakness > arm and face	08	Right frontal Lobe
Right complete hemiplegia	2	Left Internal Capsule	Left complete hemiplegia	04	Right Internal Capsule
UMN* hemiplegia and H/O sever headache, vomiting and unconsciousness	12	Cerebral hemorrhage			
UMN hemiplegia, Neck rigidity and Kerining sign	9	Sub archnoid-hemorrhage			

\* Upper Motor Neuron

**DISCUSSION**

Despite new post-stroke management strategies stroke remains a serious disease affecting not only the patient but his family as well.<sup>8</sup> Attack of stroke occur in older age group due to enhancement of atherosclerosis. In this study mean age of the patients admitted

territory and 20% of vertebro basilar artery was also observed by Razzak A. in his study<sup>10</sup>. Comparing the both sides of parietal/temporo parietal cerebral infarctions. Left parietal/temporo parietal cerebral infarction is more frequent than right side (41:19). This observation is quite comparable with study done by Ali Nawaz Khan.<sup>11</sup> In his study he found most common area of the brain involved was cortical infarction (32.3%) fol-

**TABLE II:  
LOCALIZATION OF THE CEREBRAL INFARCTION CLINICAL/VERSUS CT SCAN BRAIN FINDINGS**

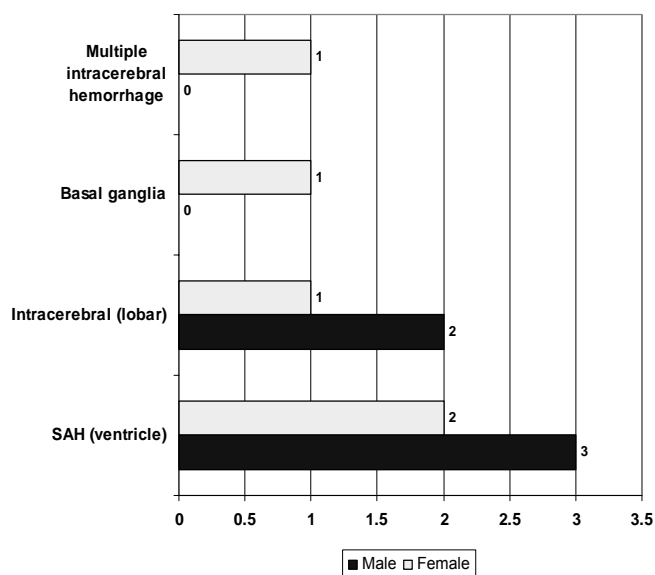
Left Side Infarction			Right Side Infarction		
Site	Clinical	CT scan brain		Clinical	CT scan brain
Parietal/ Temporo parietal lobe	43	41 (P=0.83)	Parietal/Temporo parietal lobe	25	19 (P=0.37)
Frontal lobe	7	5 (P=0.56)	Frontal lobe	8	4 (P=0.25)
Internal capsule	2	2 (P=1.0)	Internal capsule	4	3 (P=0.71)

**TABLE III:  
CEREBRAL ARTERY INVOLVEMENT**

Left middle cerebral artery	43	58%	Right middle cerebral artery	22	30%
Left anterior cerebral artery	5	6.7%	Right anterior cerebral artery	4	5.3%

**FIGURE II:**

Localization of Site of Hemorrhage on CT Scan Brain



lowed by internal capsule (25.7%)<sup>11</sup>. He also found in his study that most commonly affected artery was left middle cerebral artery and its perforate branches, followed by right middle cerebral artery and its perforating branches (32.9%) and anterior cerebral artery and its branches in (3.59%)<sup>11</sup>. In this study CT scan was inconsequential or normal in 26 patients who were clinically diagnosed as infarction or hemorrhagic stroke. Possibility of lacunar infarction could not be ruled out in those patients. This observation indicated that MRA (MR angiography) is needed in such patients for proper localization. K.S Sotaniemi et al found in his study that computed tomography failed to visual-

ized cerebrovascular lesions in 40 patients out of 386 in whom stroke was clinically diagnosed<sup>12</sup>. Out of 21 clinically diagnosed cerebral hemorrhagic stroke, in 3 (14%) patients intra cerebral lobar hemorrhage and in 5 (23%) patients ventricular hemorrhage confirmed on CT scan brain. Khan J in his study found 13 (52%) patients in whom CT scan brain confirmed the hemorrhage, out of 25 patients in whom cerebral hemorrhage was diagnosed clinically<sup>8</sup>. These observations also comparable with study done by Ali Nawaz Khan. He found 5 (15%) patients of sub arachnoids hemorrhage out of 33 patients with hemorrhagic stroke<sup>11</sup>. In our study most common site of intra cerebral hemorrhage was cerebral lobe then basal ganglia. Whereas Ali Nawaz Khan found basal ganglia hemorrhage in 39% patients. Cerebral hemorrhage in our study is over diagnosed clinically (21/10) then cerebral infarction (89/74). This defers the study done by Zahir Shah. He found that cerebral infarction tends to be over diagnosed clinically as compared to cerebral hemorrhage which tends to be under diagnosed clinically as compared with CT scan findings<sup>11</sup>.

## CONCLUSION

It was concluded from the study that cerebral infarction was more common than hemorrhage and middle cerebral artery territory infarction of both sides was more common than other cerebral artery territories. Localization of stroke on clinical basis is not always easy. Confident diagnosis requires careful case history taking, extensive neurological assessment and with the help of focal neurological deficit of a particular area.

## REFERENCES

1. Hantano S. Experience multi-centre stroke register. A preliminary report bulletin. WHO 1976; 54: 541-53.
2. Lopez AD, Mathers CD, Ezzati M, Janison DT, Murray CJ. Global and regional burden of disease and risk factors. 2001: systemic analysis of population health data. Lancet 2006;367:1747-57.
3. Vohra EA, Ahmed WO, Ali M. Etiology and prognostic factors of patients admitted for stroke. J Pak Med Assoc 2000;50(7):234-6.
4. Judith M, George AM (ed). The Atlas of Heart diseases and Stroke. 1st ed. World Health Organization and CDC. London, The Han way press, 2004.
5. Feigin VL, Lawes CM, Bennett DA, Anderson CS. Stroke epidemiology: a review of population-based studies of incidence, prevalence, and case-fatality in the late 20th century. Lancet Neurol 2003;2:43-53.
6. Biller J, Love BB. Ischemic cerebrovascular disease. In: Bradely WG, Daroff, Fenichel GM, Marsden DC (eds). Neurology in clinical practice of diagnosis and management. Philadephia, Bullerworth-Heinemann, 2000: 1125-66.
7. American Heart Association. Heart and stroke statistics-2004 update. Dallas, Am Heart Assoc 2004.
8. Khan J, Atique-ur- Rehman. Comparison of clinical diagnosis with computed tomography in ascertaining types of strokes. J Ayub Med Coll Abbottabad 2005;17(3):145-8.
9. Shah Z, Hinagul M. Risk factors and comparion of CT versus clinical findings in stroke. J Med Sci-2003; 11(1):53-8
10. Razzak A, Khan B, Baig S. CT and MRI in young stroke patients. J Pak Med Assoc 1999;49(3):66-8.
11. Khan AN, Hashmi A. To correlate the clinical picture with computed tomography scan finding in 200 cases of stroke. Pak Armed Forces Med J 2006;2:68-9.
12. Sotaniemi KA, Pyhtinen J, Myllyla VV. Correlation of clinical and computed tomography findings in stroke patients. Stroke 1990;21(11): 243-5.



### AUTHOR AFFILIATION:

**Dr. Ghulam Hussain Baloch** (*Corresponding Author*)

Assistant Professor, Department of Medicine  
Liaquat University of Medical & Health Sciences  
(LUMHS), Jamshoro, Sindh-Pakistan.

**Dr. Samiullah Shaikh**

Assistant Professor, Department of Medicine  
LUMHS, Jamshoro, Sindh-Pakistan.

**Dr. Mukhtiar Hussain Jaffery**

Senior Lecturer, Department of Medicine  
LUMHS, Jamshoro, Sindh-Pakistan.

**Dr. Suhail Ahmed Almani**

Professor, Department of Medicine  
LUMHS, Jamshoro, Sindh-Pakistan.

**Prof. Noor Muhammad Memon**

Dean Faculty of Medicine & Allied Sciences  
LUMHS, Jamshoro, Sindh-Pakistan.

**Dr. Muhammad Qasim**

Assistant Professor, Department of Medicine  
LUMHS, Jamshoro, Sindh-Pakistan.