

ILIZAROV EXTERNAL FIXATOR IN THE MANAGEMENT OF FRACTURES OF TIBIA

**Pir Abdul Latif Qureshi, Asadullah Makhdoom, Muhammad Ayoob Laghari and
Professor Khaleeque Ahmed Siddiqui**

KEY WORDS: MANAGEMENT, ILIZAROV EXTERNAL FIXATOR, FRACTURES TIBIA

ABSTRACT:

We studied 30 tibial fractures, acute and old, managed with Ilizarov external fixator in the department of Orthopaedics, Unit I, at Liaquat University of Medical & Health sciences Jamshoro-Hyderabad. All the patients were selected according to inclusion criteria and through counseling with patient and his/her relatives. Average union time was 20.13 weeks. Average time to Partial weight bearing walking was 4.46 day and average time to full weight bearing walking was 31.5 day. Average total hospital stay was 4.45 weeks. Pin site inflammation and pain were the commonest complications in our study. Close adherences to Ilizarov principles make it now possible to successfully treat a host of Orthopaedic conditions that previously were fraught with high morbidity rates and poor results.

INTRODUCTION:

The tibia is a long bone, the anterior third of which is placed subcutaneously in the leg throughout most of its length, where it is covered only by skin and a thin layer of subcutaneous tissue, with no muscle cuff around. The management of extensive and complex defects has been more challenging and often resulted in leg amputation or shortening. Limb shortening is also responsible for asymmetric gait and posture deformity. Angular deformities can be corrected by osteotomy followed by external splintage, internal fixation or external fixation. Corrective osteotomies can be closing wedge, opening wedge or dome shaped^{1,2}. When any or all of these deformities are associated with nonunion, the Ilizarov method permits the surgeon to gradually correct all deformities either simultaneously or in succession³. Limb deformities and infections once considered untreatable or treatable only by amputation, are now correctable with the use of a modern orthopaedic surgical technique, known as "The Ilizarov Method"⁴. The Ilizarov external fixator is best indicated for tibial fractures, because of its advantage of allowing early weight bearing⁵. The options so far available and practiced for the treatment of these conditions have not yielded most satisfactory results. Ilizarov method has thus proved that it was effective in the treatment of post-traumatic nonunion of the tibia where other types of treatment had failed⁶. Ilizarov method has opened new possibilities in the treatment of complex skeletal deformities⁷. Ilizarov external fixator is used to lengthen or widen bone, to correct angular rotational deformities and to immobilize fractures⁸. As an external fixator, the Ilizarov apparatus allows gradual mechanical correction of any deformity in three dimensions⁹. Ilizarov external fixator allows correction of three-dimensional deformities rotation, translation, angulation and correction of shortening, widening, lengthening and soft tissue defects¹⁰. The Ilizarov method relies on distraction neo-histogenesis and can be used to correct malalignment with minimal surgery and to overcome shortening^{11,12,13,14}.

In 1950s, G.A. Ilizarov introduced not only a new apparatus but even more importantly a new understanding of the biology of lengthening. His technique enables correction of angular, rotational, and translational osseous deformities as well as restoration of limb length equality¹⁵⁻¹⁶. The system consists of many parts and allows application to almost any limb segment, limb size or limb deformity. The

Ilizarov technique for complex nonunions has a high rate of success in achieving union and eradicating infection, bone loss and malalignment¹⁷. It has produced excellent results where the existing methods have failed to achieve even minimum acceptable. The results of treatment were always: healing of the nonunion, functional recovery of the limb, correction of leg length discrepancy, recovery of mechanical axis⁸.

MATERIAL & METHODS:

This descriptive study was conducted at department of orthopaedics, unit-i, Liaquat University Hospital, Hyderabad and Jamshoro. The duration of study was three year, from december 2000 to december 2003, 30 tibial fractures. Study design was descriptive. Inclusion criteria of study was open, comminuted and segmental fractures of tibia, close, comminuted and segmental fractures of tibia, open and closed fractures of tibia with nerve injury and post traumatic malunion and non-union (infected and non-infected). Exclusion criteria was closed transverse fractures of tibia, open fractures of tibia that requires any kind of flap to cover the naked bone, tibial fractures with neurovascular deficit.

DATA COLLECTION PROCEDURE:

All patients were admitted to Orthopaedic unit I, with Tibial fractures, either through casualty or through out patient department, direct arrivals or those mishandled by potters and quakes selected according to inclusion criteria were treated with “**ILIZAROV EXTERNAL FIXATOR TECHNIQUE**”. All cases were followed with immediate postoperative radiographs and clinical assessment. Then followed through OPD weekly and then twice monthly when discharged from hospital otherwise thrice weekly radiographs had taken and alternate dressings done in ward. Record of all the cases were maintained in the proforma which include all the informations regarding the patients history, status of his/her general condition and wounds and fractures from the time of arrival to discharge. Also, include clinical and radiological assessments in the review clinics with view of healing of wounds, union of fracture, complications, total hospital stay, weight bearing status and functional outcome. In all cases healing was assessed by radiological as well clinical examination and fracture were labeled united when the fracture line obliterated and not visible radiological and no movement was seen clinically at fracture site.

DATA ANALYSIS:

Mean, Median, Mode, Frequencies, and Percentages & Standard deviations were calculated by SPSS version 10.

OPERATIVE PROCEDURE:

After complete pre-operative investigations & assessment by pre-anesthetic clinic, the patients were placed on operating table. Usually epidural anesthesia had been given to all patients. After draping, the first transverse wire was passed proximal to the fracture site and then ring was fastened after tensioning the wire either with wire tnesioner or manually with spanners and other two wires were passed at atleast 45⁰ to first wire. We had need 1.8mm plain wires at diaphysis and Olive tip at metaphysis. Than 2nd construct made distal to the fracture site. The usual distance between construct proximal and distal to fracture was 2 – 3 cm. Then another constructs were made proximal and distal to previous constructs respectively and fastened with threaded rods. Then getting reduction in all planes, rings proximal and distal to fracture site fastened with threaded rods. Most of the time, we had used Image intensifier to achieve reduction and near normal alignment of the fracture.

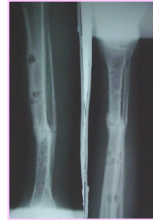
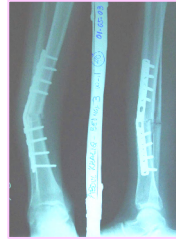
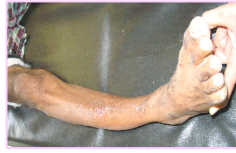Sometimes, we used drops wires and attached them with the help of posts to rings. All the rings were larger of 2-finger breaths to diameter of leg over anterior aspect and 3-finger breaths to posterior aspect of leg. For each ring, minimum of 3 wires were used. While inserting the wires, they were first gently pushed upto the bone through skin and then drilled with power drill. As soon as they come out through other cortex, they were hammered gently to get out to other side. Muscles were at their maximum length while inserting the pins and all the wires were passed through safe zones. All the wires were tensionized before fasten to rings either with wire tensioner or manually with spanners at both ends simultaneously on plain wires and only opposite end on olive tip wires. The wire sites were dressed with hydrogen per oxide and pyodiene solution soaked gauzes.

POST OPERATIVE MANAGEMENT

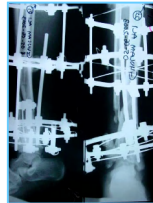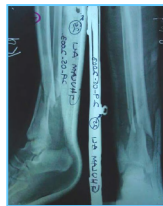On return from Operation Theater, patients were allowed with partial weight bearing walking with close fractures after 6 hours and on 2nd or 3rd day with open fracture according to the condition of wound and patient. Usually they were allowed full weight bearing walking in week's time if they tolerated. Parental antibiotics were given upto 3rd – 4th day for closed fractures and up to eradication of infection or wound healing for open and infected fractures. Epidural analgesia was used for 2 – 3 days usually than shifted to either perentral or oral analgesics. Weekly alternate compression / distraction at fracture site started usually after 10 days of application of Ilizarov external fixator. Check x-rays were done on next day and adjustments were done on 2nd or 3rd day if required. Patients were trained for daily wash of fixator, pins, pin care and mobility of joints and Quads excercises.

FOLLOW-UP IN OPD

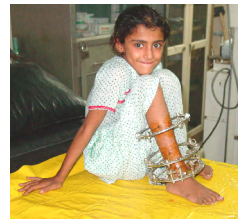
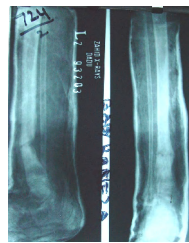In the follow up in OPD, fixators were checked thoroughly, each and every nut and bolt tightened, wires tensionized if needed, pin sites were cleaned with pyodine solution and hydrogen per oxide and washed thoroughly with Normal saline. If there was any deep pin tract infection, or pin loosening, the patients were readmitted for surgical toilets and treated according to culture and sensitivity report isolated organisms and readjustments of fixators respectively. Radiographs were taken at every 3rd week. Fixators were dynamized on callus formation and removed after 3 – 4 weeks of dynamization. Before removal, fixators were dismantled first without anesthesia and fracture site was examined for movement and tenderness. If there was any tenderness and mobility at fracture site, fixators remained in situ for more 3-4 weeks. All the fixators had been removed without anesthesia as an OPD procedure. First, the distal rings were removed and the wires were taken out with help of chuck and then similarly proximal construct removed. All the pin site wounds were washed with saline and pyodine soaked gauzes and above or below knee walking cast were applied according to the fracture site for 2 weeks and then radiographs were taken with out cast and were allowed full weight bearing walking and advised first monthly and then thrice a year for follow up in OPD.



MALUNION



PILON FRACTURE



PESUDOARTHROSIS RT. TIBIA

Table 1 **MODE OF INJURY**

S.NO	MODE OF INJURY	NO. OF PATIENTS	% AGE
1	RTA – MOTOR BIKE VICITM	7	23.33
2	RTA – PEDISTARIAN HIT	8	26.66
3	RTA – HEAD ON COLLISION	6	20
4	FALL DURING WALKING	3	10
5	FALL FROM HIEGHT	3	10
6	GUN SHOT INJURY	2	6.66
7	FALLEN HEAVY OBJECT	1	3.33

Table 2 **OPEN FRACTURES ACCORDING TO GUSTILO CLASSIFICATION**

S.NO	GRADE	NO. OF PATIENTS	% AGE
1	GI	3	10
2	GII	4	13.33
3	GIIIA	0	0
4	GIIB	6	20
5	GIIC	0	0

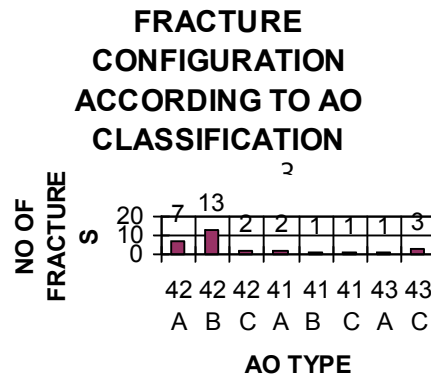
Table 3 **TIME TO UNION IN WEEKS**

MINIMUM (WEEKS)	MAXIMUM (WEEKS)	MEAN (WEEKS)
10.86	59.29	20.13

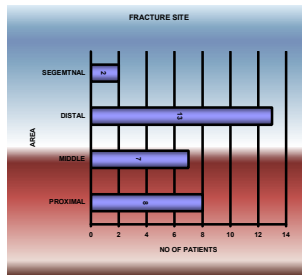
Table 4 **TIME TO FULL WIEGHT BEARING WALKING**

MINIMUM (DAY)	MAXIMUM (DAY)	MEAN (DAY)
7 TH DAY	157 TH DAY	31.5 TH DAY

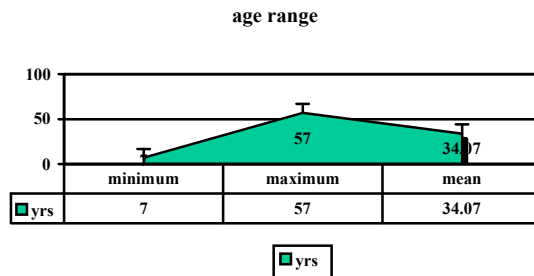
GRAPH 1



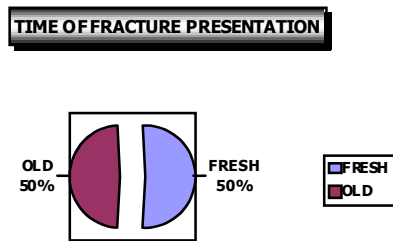
GRAPH 2 FRACTURE SITE



GRAPH3 AGE RANGE



GRAPH 4 FRACTURE PRESENTATION TIME



OBSERVATIONS & CONCLUSION

30 consecutive patients with 30 tibial fractures were treated using the Ilizarov method and apparatus. Injuries included 17 closed fractures (56.66%) and 13 open fractures (43.33%). Nineteen (63.33%) patients had right tibial involvement and Eleven (36.66%) had left tibial involvement. According to Gustilo classification for open fractures, there were three Grade I open (10%), four Grade II open (13.33%), and six Grade IIIB open (20%) tibial fractures. Majority of them, twenty one, had Road Traffic Accident (70%), three fell on ground during walking (10%), three fell from height (10%), two gunshot injury (6.66%) and one patient had fallen heavy object (3.33%). Age ranged from 7 to 57 years with mean age 34.07 years. There were twenty-seven male (90%) and three were female (10%). Fifteen patients (50%) had old fracture and fifteen patients (50%) had acute injury. Eight patients (26.66%) had Proximal Tibial fracture, seven (23.33%) had Middle, thirteen (43.33%) had Distal and two patients (6.66%) had segmental fracture. Six patients (20%) at the time of arrival had Infected Non-union, four (13.33%) had Non-infected hypertrophic non-union, one (3.33%) had wound infection, one (3.33%) had infected Malunion, one (3.33%) Mal-union Non-infected and one (3.33%) had Pseudoarthrosis. According to AO Classification 41A type Fracture were two (6.66%), 41B was one (3.33%), 41C was one (3.33%), 42A were seven (23.33%), 42B were thirteen (43.33%), 42C were two (6.66%), 43A was one (3.33%), 43C were three (9.99%). **Union time** was 10.86 weeks to 59.29 weeks with average of 20.13 weeks. Average time to Partial weight bearing walking was 4.46 day with range from 1st to 22nd day and 31.5th day average time to full weight bearing walking with range from 7th to 157th day to application of Ilizarov External Fixator. Average total **hospital stay** was 4.45 weeks with range from 0.29 weeks to 23.29 weeks. Twenty nine patients had Pin site inflammation (96.66%), twenty eight had Pain during walking (93.33%), twenty five had Pin site Hyper granulation (83.33%), twenty four had Pain at rest (80%), twenty two had Pin loosening (73.33%), twenty had Superficial Pin tract infection & swelling of leg (66.66%) each, thirteen had Deep Pin tract infection (43.33%), eleven had ankle joint stiffness (36%), seven had Delayed union (23.33%), three had Pin breakage and Knee joint stiffness (10%) each, Vascular injury (3.33%), non-union (3.33%) & mal-union (3.33%) occurred in one patient each.

In our opinion Ilizarov external fixator is remarkably versatile with each assemblage custom-made for any particular problem. The results are Marvelous but there is poor patient acceptance because of pain and cumbersome size and shape of the frame.

Because of less encouragement from Orthopaedic surgeons due to tediousness of the procedure and dressings and prolonged follow up most of patients refused application of Ilizarov our institutions.

We are convinced that this appliance should be more frequently used to achieve better results where the conventional methods are helpless

DISCUSSION

In our study Union time varied from 10.86 weeks to 59.29 weeks with average of 20.13 weeks. Kumar & Whittle in a study of treatment of complex fractures of the tibial plateau with circular wire external fixation says "all fractures united at an average of 173 days i.e 24.71 weeks (range 50 to 415 days) i.e 7.14 to 59.28 weeks)"¹⁸. Dr. Khaleeque Ahmed Siddiqui in his study on external fixator in open and infected fractures says "the average time taken to bony union was 17.3 weeks in tibial fractures"¹⁹. Behrens & Searls in their study of external fixation of the tibia showed average union time of 186 days i.e 26.57 weeks²⁰.

Average time to Partial weight bearing walking was 4.46 day with range from 1 to 22 days and average time to full weight bearing walking was 31.5 day with range from 7 to 157 days from the application of Ilizarov External Fixator in our study. Behrens & Searls in their study of external fixation of the tibia showed 36 days average time to partial weight bearing walking and 65 days to full weight bearing walking²⁰. In one study, forty-one unstable tibial fractures with substantial loss of bone were treated with simultaneous compression of the fracture site and adjacent lengthening of the affected bone with Ilizarov external fixator by Tucker, Kendra & Kinnebrew, showed "all of the fractures healed with out bone grafting with the time to union ranging form 12 to 47 weeks (mean 25.6 weeks)"²¹. Average total hospital stay was 4.45 weeks with range from 0.29 weeks to 23.29 weeks. Twenty nine patients had Pin site inflammation (96.66%), twenty eight had Pain during walking (93.33%), twenty five had Pin site Hyper granulation (83.33%), twenty four had Pain at rest (80%), twenty two had Pin loosening (73.33%), twenty had Superficial Pin tract infection & swelling of leg (66.66%) each, thirteen had Deep Pin tract infection (43.33%), eleven had ankle joint stiffness (36%), seven had Delayed union (23.33%), three had Pin breakage and Knee joint stiffness (10%) each, and vascular injury (3.33%) , non-union (3.33%) & mal-union (3.33%) occurred in one patient each. In a study of lower limb angular deformity correction using the Ilizarov method by Shamim A, Mehmood A, Chaudhry FA, & Ayesha Mehmood, showed "every patient (100%) developed at least one minor pin tract infection of the superficial soft tissues around the pin. All the superficial pin tract infections were treated with increased pin tract care and oral antibiotics. Pin tract osteomyelitis developed in one patient (4%) who underwent a high tibial angular correction for genu varum resulting form medial compartment arthritis of the knee. This settled uneventfully after curettage following fixator removal. One patient (4%) who presented with severe bowing of the tibia and nonunion at the site of a previous unsuccessful corrective osteotomy refractured at the nonunion site after bifocal treatment. The refractured however healed solidly after reapplication of the fixator. One patient (4%) with genu valgum secondary to a malunited distal femoral physeal fracture developed premature consolidation at the low energy supracondylar osteotomy and required a repeat osteotomy. there were no cases of wire or fixator component breakage or neurovascular injury"²². In a study of use of external fixator in the management of open and infected fractures of long bones by Wazahat Huasain warraich, says,

“wound infection, pin tract infection, loosening of pins, non-union, delayed union, mal-union, and joint stiffness were the main complications with application of external fixator in open fracture of long bones”²³.

“The Ilizarov technique of transosseous fixation has spread throughout the world. Clinical experience has revealed many recurrent problems, which are mainly due to: i) A long time required to assemble the apparatus in the operating theatre, ii) Difficulty of the method, iii) Transosseous fixation has poor patient tolerance in the case of proximal humerus and femur, and iv) Difficulties in the postoperative follow up management”²⁴. The Ilizarov technique is very versatile and rewarding. Although it is a long treatment and needs patience both from the patient and the family but it can solve the problems, which cannot be dealt with conventional methods²⁵.

REFERENCES

- 1 Sheffer MM, Peterson HA. Opening-wedge osteotomy for angular deformities of long bones in children. *J Bone Joint Surg Am*, 1994 Mar; 76 (3): 325-34.
- 2 Sundaram NA, Hallett JP, Sullivan MF. Dome osteotomy of the tibia for osteoarthritis of the knee. *J Bone Joint Surg Br* 1986 Nov ; 68 (5) : 782-6.
- 3 Green SA. Ilizarov type treatment of nonunion, malunion and post traumatic shortening. In: Chapman M W. *Oper Orthop BR* 1993: 985-1000.
- 4 Syed Rifat Ali Zaidi .The Ilizarov method - A modern orthopaedic procedure for your patients. *Rawal MED J Sep* 2000;3:45-50.
- 5 Pavolini B, Maritato M, Turelli L, Arienzo M. The Ilizarov fixator in trauma. *J Orthop Sci*.2000;5:108-13.
- 6 Tranquilly LP, Merolli A, Perrone V, Caruso L, Giannotta L. The effectiveness of the circular fixator in the treatment of post-traumatic nonunion of the tibia. *Chir Organi Mov* 2000 ;85:235-42.
- 7 Dal Monte A, Donzelli. Tibial lengthening according to Ilizarov in congenital hypoplasia of leg. *J Pediatr Orthop* 1987; 7:135-38.
- 8 Newschwander GE, N Dunst RM. Limb lengthening with Ilizarov external fixator. *Orthop Nurs* 1989; 8: 15-21.
- 9 Mateen MA. Ilizarov techniques in orthopaedic surgery. *J Surg (PIMS)*2001;23:24:10-12.
- 10 Jauerling PR. Organizing and implementing an Ilizarov programme. *Orthop Nurse* 1990; 9:47-55.
- 11 Cattaneo R, Catagni M., Johnson E.E. the treatment of infected nonunions and segmental defects of the tibia by the method of Ilizarov. *Clin. Orthop.*, 1992; 280: 143-152.
- 12 Paley D, Chaudhry M, Pirone AM, Lentz P, Kautz D. Treatment of malunions and malnonunions of the femur and tibia by detailed preoperative planning and the Ilizarov techniques. *Orthop. Clin. North Am.*,1990; 21: 667-691.
- 13 Ilizarov GA. Clinical applications of the tension stress effect for limb lengthening. *Clin. Orthop.* ,1990;250:8-26.
- 14 Stanitski DF. Treatment of deformity secondary to metabolic bone disease with the Ilizarov technique. *Clin Orthop* 1994 Apr; (301):38-41.

-
- 15 R.J Velazquez, D.F. Bell, Armstrong et al complications of use of Ilizarov technique in correction of limb deformities in children. J Bone Joint Surg Am, 1993 Aug; 76 (3): 1148-1156.
 - 16 Ilizarov G.A. Clinical application of the tension stress effect for limb lengthening . Clinical Orthopaedics 1990, P-8-26.
 - 17 Laursen MB, Lass P, Chirstensen KS, Ilizarov treatment of tibial nonunions results in 16 cases. Acta Orthop Belg 2000 ;66:279-85.
 - 18 Kumar A, Whittle AP. Treatment of complex (Schatzker type VI) fractures of the tibial plateau with circular wire external fixation: retrospective case review. J Orthop Trauma 2000 Jun-jul; 14(5):339-344.
 - 19 Siddiqui KA, Mughal KM, Akhtar AB. External fixator in open and infected fractures. The J Pak Orthop Asso Feb 1995; 10(1) : 1-9.
 - 20 Behrens F, Searls K. External fixation of the tibia. Basic concepts and prospective evaluation. J Bone Joint Surg (Br) 1986; 68-B: 246-254.
 - 21 Tucker HB, Kendra JC, Kinnebrew TF. Management of unstable open and closed tibial fractures using the Ilizarov method. Clin Orthop, 1992; 280:125-135.
 - 22 Shamim A, Mehmood A, Chaudhry FA, Ayesha M. Lower limb angular deformity correction using the Ilizarov method. The J Pak Orthop Asso Aug 2001; 13(2) : 101-105.
 - 23 Warraich WH, Ayaz A, Mahboob I, Suhail MT. Use of external fixator in the management of open and infected fractures of long bones. The J Pak Orthop Asso Aug 2001; 13(2) : 125-127.
 - 24 Mateen MA. Ilizarov Techniques in Orthopedic Surgery. J Surg Dec 2001;23-24:10-2.
 - 25 Saleem M, Hill R, Sohail T. Use of Ilizarov method on tibial bone children. The J Pak Orthop Asso Jan 2001; 12(1) : 16-23.