

Radiological Indicators for Determination of Age of Consent and Criminal Responsibility

Nizamuddin Memon, Muhammad Umar Memon, Khairunissa Memon, Hirra Junejo, Jawairia Memon

ABSTRACT

OBJECTIVES: To establish radiological markers, by ossification form of appearances and fusion for determination of Medico legal important ages for consent and criminal responsibility, for our population.

STUDY DESIGN: Perspective observational study

SETTING: Department of Radiology and Imaging, Liaquat University Hospital Jamshoro / Hyderabad Sindh.

STUDY PERIOD: June 2006 to December 2008.

METHOD: Total 1381 Subjects comprising of 617 female and 764 male, free from any musculo-skeletal, nutritional and endocrinal disorder and confirmed dates of births were selected, representing the population of Hyderabad city and adjoining areas. The Subjects were divided into 9 groups on the basis of their age and purpose of study. Radiographs of wrist, elbow, shoulder and hip were taken in accordance to the age group and anticipated findings and radiological changes were observed and recorded.

RESULTS: Radiograph of wrist showing ossification of trapezoid at the age of 7 years and pisi-form at 12 years in both sexes in 100% of cases proved to be a good indicator of the required age groups. fusion of Epiphysis distal Radius and ulna, proximal Hummers and iliuc crest can be relied upon as age indicator in Females and Males from 16 to 18 years

CONCLUSION: The outcome of this study provides more accuracy with a margin of error of ± 2 months and can be utilized for our population with confidence in medico legal disputes.

KEY WORDS: Medicolegal, consent, criminal responsibility, Radiology, Ossification, Forensic Medicine.

INTRODUCTION

In law, punishment is entirely based on criminal responsibility and this in turn is highly dependent on the age of the person¹. Similarly grant of certain civil right also proportionate certain age groups².

From the point of view of criminal responsibility in Pakistani law, ages below 7 years, between 7-12 years and from 12-18 years are crucial and for giving consent, ages of 12,16 and 18 are important³.

The dependence on age, for the form and quantum of punishment, exercising of certain privileges and restriction of certain acts though done in good faith, requires an unequivocal proof of age. The use of the objective indicator of age can avoid unnecessary litigations as well would meet the ends of justice. Courts very often refer the cases, particularly those falling on border line category, for medical opinion before finalizing their verdict.³

Amongst all the determinants of age, radiological examination of bone ends has shown accuracy and reliability acceptable to medical profession and the legal fraternity⁴.

This study is aimed to determine the bony ossification pattern at the ages, 7, 12, 16 and 18 years. This study would certainly help the medical professionals, law enforcers, Bar, bench and even the public at large.

MATERIAL AND METHOD

Subjects representing the heterogeneous population of the Hyderabad city and surroundings were selected from schools, colleges along with adolescent employees engaged in various professions and activities having confirmed dates of births. Only the subjects free from musculoskeletal, nutritional and endocrine disorders were included in this study. The parents in case of children and adolescent individuals were informed about the purpose and methodology of the study with an assurance that the data will not be divulged or used for any other purpose. A consent form was designed and presented to the parents of the children and grown up individuals for volunteering willingness for the inclusion of child /individual in this study program.

The radiographs of hands, wrists, elbow, shoulder and

pelvis necessary for the specific age group of the subject were taken in the Department of Radiology and Imaging, Liaquat University Hospital Jamshoro/Hyderabad Sindh, to observe the ossification activity of various bones. Sophisticated (conventional) X-ray machines, 300 and 500 MA and also 50 MA portable machines were used when become necessary to take on spot radiographs in the schools.

The usual method required a single radiograph of the required area posterior-anterior view involving only a small radiation doze without significant bone marrow or gonadel exposure. Additionally lead sheets were used for enhanced protection.

Considering Medico-legal objectives of the study in mind, focus is directed to age groups 7, 12, 14, 16, and 18 years being the decisive groups in the medico-legal context. For the purpose of the study, the age groups were divided into 8 categories labeling them group A to H, indicating age group A (6-7 years), B (11-12 years), C (12-13 years), D (13-14 years), E (14-15 years), F (15-16 years), G (16-17 years) and H (17-18 years).

This division was done for comprehensive and closer study of changes that could have been possibly occurred with in a year's time and also to check border line cases

The radiographs were observed and interpreted by the authors and the findings were recorded on a pre-designed Performa and conclusions were tabulated.

RESULTS

Total subjects studied numbered 1381 comprising of 617 (44.7%) Female and 764 (55.3%) males (Table I), were divided in 8 groups such as: A, age (6-7 years) 124; B (11-12 years) 167; C (12-13 years) 200; D (13-14 years) 198; E (14-15 years) 157; F (15-16 years) 208; G(16-17 years) 176; H (17-18 years) 133.

For age group 7 and 12 years, Radiograph of the wrist area displayed promising results, showing ossification of trapezoid and pisiform bones respectively. However females are advanced than males showing ossification of trapezoid at 6 years. Additionally distal ulna showed appearance of epiphysis at 7 years in females and at 7 years and 9 months in males. At the age of 14-15, fusion is seen in all the epiphysis at elbow in females but only fusion of lateral epicondyles in males is observed. At 16 years of age, fusion of epiphyses at elbow and distal radius and ulna showing fusion in females but in males distal ulna is found in process. At the age of 18, proximal end of humerus bone in both sexes showing fusion, whereas fusion of iliac crest in females also observed, males took another 10 months to match this finding to their female counter parts.

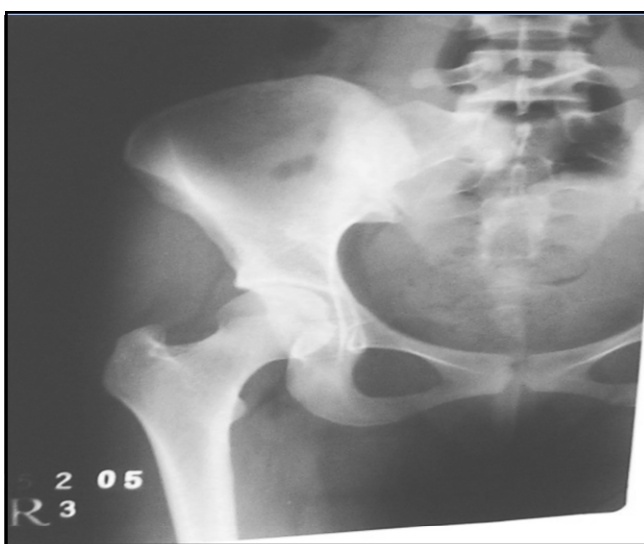
FIGURE I: FEMALE: FUSION OF EPIPHYSES SEEN AT ELBOW AGE: 14 YEARS AND 10 MONTHS

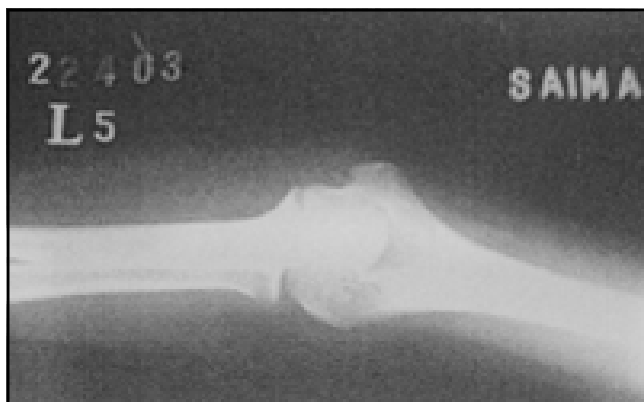

FIGURE II: MALE: FUSION OF EPIPHYSES OF DISTAL RADIUS AND ULNA SEEN AGE: 16 YEARS AND 10 MONTHS

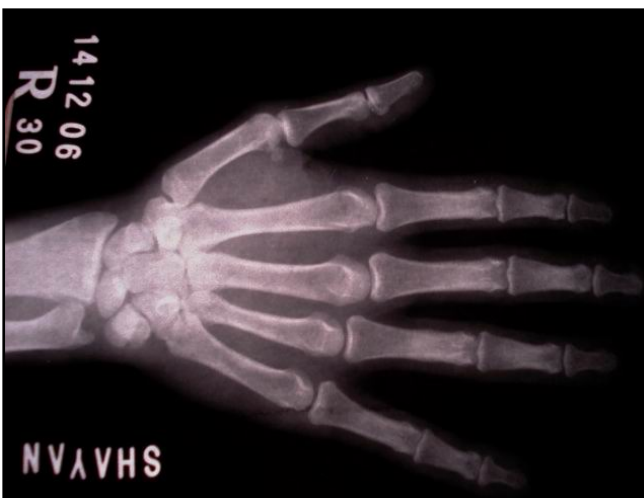

FIGURE III: FUSION OF ILLIAC CREST IN FEMALE AGE: 17 YEARS AND 10 MONTHS



**TABLE I:
DIVISION OF AGE GROUPS ALONG WITH THEIR IMPORTANCE (MEDICAL - LEGAL - SOCIAL)**

Group	Appearance and Fusion Epiphyses	Number of Subjects			Importance
	Year Month-Day (Y-M-D)	Females (F)	Males (M)	Total	
A <u>6 Yrs – 7 Yrs</u>	Females: 7 Carpals Males: 7 Carpals (7 Years) Distal Ulna (F and M) Females: 7 to 8 years	64	60	124	Medical, Legal and Social - Skeletal Maturity
B <u>11 Yrs–12 Yrs</u>	Carpals: 08 Females and Males	76	91	167	Medical and Legal - Capable of committing crime if there is sufficient maturity of mind 7 to 12 yrs
C <u>12 Yrs–13 Yrs</u>	Females and Males: All epiphyses present at ELBOW.	88	112	200	Medical, Legal and Social • Puberty (Female) • Issuance of Passport at 12 years -Skeletal Maturity
D <u>13 Yrs–14 Yrs</u>	Females and Males Epiphyses of ELBOW not fused.	88	110	198	Medical, Legal and Social FEMALES Puberty -Skeletal Maturity
E <u>14 Yrs–15 Yrs</u> Fig: No. I	ELBOW Females Fusion of Epiphyses. Males Only fusion of epiphyses of lateral epicondyle 14-10-00 Appearance of Epiphyses of ILIAC CREST Females: 14-00-00 Males: 14-10-00	79	96	175	Medical, Legal and Social MALES • Puberty -Skeletal Maturity
F <u>15 Yrs–16 Yrs</u>	Fusion of Epiphyses FEMALES: DISTAL RADIUS and ULNA MALES: Metacarpals • ELBOW	97	111	208	Social and Legal 16 YEARS • Eligibility for valid consent. -Skeletal Maturity
G <u>16 Yrs–17 Yrs</u> Fig: No. II	Fusion of Epiphyses FEMALES: Proximal Humerus Y-M-D MALES: 16-10-00 Distal ULNA and Radius	67	109	176	Social and Legal 16 YEARS FEMALES: • Marriage contract. -Skeletal Maturity
H <u>17 Yrs–18 Yrs</u> Fig: No. III Fig: No. IV	Fusion of Epiphyses FEMALES: Y-M-D ILIAC CREST 17-10-00 MALES: Proximal Humerus 17-10-00 Iliac Crest After 18 years 18-10-00	58	75	133	Social and Legal • Distinction of between juvenile and Adult Prisoners. • Marriage contract (Male 18 Years) • Granting civil Rights • I .D Card and Driving License • Casting Vote • Property maintenance and disposal -Skeletal Maturity
	TOTAL	617	764	1381	-Skeletal Maturity

TABLE II: MEDICO LEGAL IMPORTANCE OF AGE GROUPS STUDIED WITH REGARD TO CONSENT AND CRIMINAL RESPONSIBILITY

Age Consent	Importance
12 years	Consent for physical examination ⁵ .
15 years	Puberty.
16 years	Matrimonial alliance by female partner. valid consent for sexual intercourse ⁶
18 years	Consent for major surgery, matrimonial alliance by male partner ⁶ .
Criminal Responsibility	
7 years	Incapable of committing crime ⁷
7-12 years	Guilty of offence provided attained sufficient degree of mental maturity ⁸ .
12-18 years	Guilty tried under juvenile justice system ⁹ .

FIGURE IV: MALE: FUSION OF EPIPHYSES FOR PROXIMAL HUMERUS AGE: 17 YEARS AND 10 MONTHS

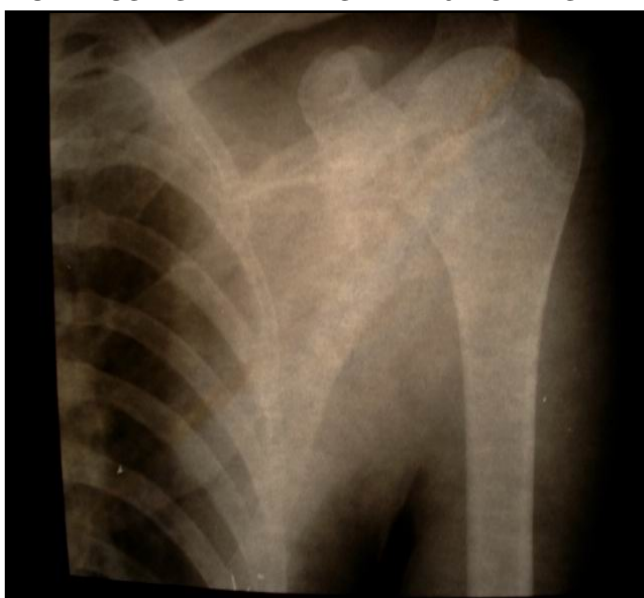


TABLE III: A COMPARISON OF LINES OF FUSION FOR THE DISTAL EPIPHYSES OF THE RADIUS, ULNA AND ILIAC CREST BETWEEN OTHER AUTHORS AND THE PRESENT STUDY

Author (with year)	Subjects	Fusion in years Y-M-D				Fusion in years Y-M-D	
		Radius		Ulna		Iliac Crest	
		Females	Males	Females	Males	Females	Males
Davis Parsons (1927)	English	--	--	--	--	--	23
Paterson (1929)	English	19-20	21	19-20	21	--	--
Sindos and Derr (1931)	Egyptians	--	19-20	--	19-20	--	--
Galstaun (1937)	Bengalis Indian	16	18	17	18.5	17-19	19-20
Flecker (1942)	Australians	18	19	17	19		
Greulich and Pyle ²¹ (1942)	White American of Upper Socioeconomic class	17	--	17	18		
Mackay (1952)	East Africans	--	--	--	--		
Hansman (1962)	Americans	16	18	16	18		
Krogman ²⁶ (1962)	English	--	--	--	--	18-19	--
Rikhasor M and Qureshi (1991)	Pakistanis	16	18	15.5	17.5		
Present study (2008)	Pakistanis	15-10-00	16-10-00	15-10-00	16-09-00	17-10-00	18-10-00

DISCUSSION

The statute or codified law is distinguished as civil law and criminal law. Where civil law deals with the rights of citizen in a particular state, Criminal law involves crime and its punishment. In both categories age of an individual becomes a major concern. Nuptial bonds, voting right, selling or buying of property, consent regarding contracts are the examples of cases that comes under the ambit of civil law whereas crime related cases like physical and sexual assault, kidnaping etc, are tried and punished by criminal courts.

Criminal justice requires that the accused has acted voluntarily and this philosophy has given way to general presumptions and exceptions in law. Immaturity, insanity and intoxication; all these factors negate or least mitigate criminal responsibility¹⁰. The presumptions and exceptions are well reflected in the Pakistan penal code¹¹. (P.P.C)

Section 82 P.P.C reads that child of less than 7 years in unable to commit crime. Section 83 PPC states that child of 7-12 years is presumed to be capable of committing an offence if he has attained maturity of understanding the nature and consequence of his conduct and delinquent juveniles who are below 18 years of age, are not sentenced to death and are sent to borstal jail. Section 89 says that child below 12 years can not give consent for physical examination whereas consent for a major surgical operation can only be valid if given by person above 18 years of age. Marriage at person's own will is legally acceptable when the bride has attained 16 years and bridegroom 18 years of age. Due to non availability or poorly maintained or deliberately manipulated records, reliance can not be made on the presented age document¹². The lawyers under 'must-win' compulsion can exploit the condition of age to favor his client, ignoring the dispensation of justice. This situation requires an objective and reliable method of studying age

Radiological study of the bones to observe their ossification activity has long been used by various authors, throughout the globe for age estimation with promising results¹³. Many have compiled and published their data and even printed radiological atlas representing their population's figures^{14, 15}. This foreign data is being used by our colleagues, especially in medico legal context. As the racial, socio- economic and environmental factors play their vital role in human growth and subsequent maturity, the observations of those

authors can not match our pattern of bony growth and changes¹⁶. The data compiled by the western or even eastern authors, if applied for medico legal purpose, poses threat to dispensation of justice. However in the present study which out numbered the quantum of cases studied by others, show both comparable and contrasting findings.

Our study of carpal bones shows that in both female and male subjects, trapezoid bone is ossified at the age of 7 years, where as the study of other authors' shows variability ranging from 4 to 7 years.(Refer table in females trapezoid, however shows some what early appearance. For determination of medico legal important age of 7 years, ossification of trapezoid bone in wrist x-ray can be labeled as a milestone.

At elbow, all the epiphysis of lateral epicondyle, proximal ulna and radius, and medial epicondyle are fused in females between 14-15 years of age where as males are at least 10 months later in showing the same picture. For estimation of age of puberty (14-15) in female finding at elbow joint can be taken as indicator.

For appearance of distal epiphysis of radius and ulna, this study shows agreement with other Pakistani researchers, but shows marked contrast with observations of Galstaun for Bengalis subjects and flecker for Australians showing 10-11 years and 6 years respectively.

Fusion of epiphysis of distal radius and ulna show time contrast of 2 years, earlier, as compared to other international authors and for about half year earlier when compared with local authors.

Iliac crest also shows 2 year early fusion both in male and female subjects than their English counterparts. The study resulted in accuracy of age estimation with a margin of error ± 2 months, the medical professionals when called for, can rely on the presented data for our community instead depending on international author's data that show contrasting results on many areas (Table No. III)

CONCLUSION

As the age groups mentioned above come under debate in courts, apparent physique and presented document regarding age are misleading, radiological examination becomes the appropriate alternate. This study concludes that, for our population:

1)- Determination age of 7 years, x-ray hand and wrist, showing ossification of trapezoid bone and for

12 years ossification of pisiform bone in both sexes is a good indicator.

2)- Age group 16, Fusion of epiphyses of Distal Radius and Ulna (wrist x-ray) for female and fusion of epiphyses of phalanges, metacarpals and elbow (hand and elbow x-rays) for male can be regarded as definite finding

3)- Age group 18, reliance can be made on Fusion of epiphysis of iliac crest (x-ray pelvis) for female and fusion of epiphysis of proximal humerus (shoulder area) for males.

4)- Recommended radiographs with suggested areas for specific age groups are:

7-12 years (Hand and Elbow), 12-16 years (Elbow + Wrist) and 16-18 years (Wrist + Shoulder + Hip).

ACKNOWLEDGMENT

The author Acknowledges Higher Education commission of Pakistan for the approval and funding and support throughout the project. Author also acknowledges the support by various schools principals, teachers and the parents for understanding the importance of Project and giving consent and helping in providing the subjects to be included in the study. This is also to acknowledge the entire staff of department of diagnostic Radiology and Imaging, Hyderabad sindh Pakistan for helping me for collection and preservation of the required record.

REFERENCES

1. Rao NG, ed. Text book of Forensic Medicine and Toxicology. 2nd edition. New Delhi: Jaypee Brothers;2010.
2. Aggarwal G, ed. Forensic medicine and toxicology smart study series. Gurgaon: Elsevier; 2009.
3. Parikh CK, ed. Parikh's text book of medical jurisprudence forensic medicine and toxicology. 6th edition. New Delhi: CBS publishers; 1999.
4. Vi JK. Text book of forensic medicine and toxicology. 4th edition. New Delhi: Elsevier India; 2009.
5. Dikshit PC. Text book of forensic medicine and toxicology. New Delhi: Peepee Publishers; 2007.
6. Protection of women (Criminal Law Amendment) act, 2006. Available at URL: <http://www/Pakistani.org/page1-11>.
7. Rikhasor M, Sajda. Time of appearance of ossification centers of Hand and wrist. Pak J Med 1992.
8. Srivastav A, Sarwat PK, Agarwal SK. A study of wrist ossification for age estimation of pediatric group in central Rajasthan. J Indian Assoc Forensic Med 2004;26:132-5.
9. Juvenile justice system ordinance,2000(xx ii of 2000). Available at URL: http://www.Karachi-east.org/dec_files/juvenile.doc.
10. Awan NR. principles and practice of Forensic Medicine; 1st edn, Lahore; Zubair Book Depot; 2009, 4-10.
11. <http://www.pakistani.org/pakistan/legislation/1860/actXLVof1860.html>
12. Craig G, ed. Grainger and Allison's Diagnostic Radiology- A text book of medical imaging. 4th edition. Edinburgh: Churchill livingstone; 2002.
13. Bu Ken B, Sfat AA, Yazici B, Bu Ken E, Mayda As. Is the assessment of bone age by the Greulich- pyle method reliable at Forensic age estimation of Turkish children. Forensic Sci Int 2007;173(2-3):146-53.
14. Zafar AM, Nadeem N, Huseny, Ahmed MN. An appraisal of Greulich- Pyle Atlas for Skeletal age assessment in Pakistan. J Pak Med Assoc
15. Nahid G, Atodorrhahim A, Garib SM, Anvar E. Assessment of bone age in Kurdish children in Iran. Pak J Med Sci 2010;126(1):36-9.
16. Buken B, Erzenin OU, Buken E, Safak, AA, Yazici B, Erlerl Z. Comparison of the tree age estimation: This is more reliable for Turkish children. Forensic Sci Int 2009;183(1-3):103.
17. Paterson RS. A radiological investigation of the epiphyses of long bones. TA Anat 1929;64:28-46
18. Sidhom G, Derry DE. Dates of some Epiphyses in Egyptians from x-ray photographs. F Anats 1931;65;169-211
19. Galstaun GA. A study of ossification as observed in Indian subjects. J Med Res 1937;25:267-327.
20. Flecker H. Time of appearance of ossification centers as observed by Roent Gengraphic methods. Am J Radiol 1999; 47:97-159.
21. Grulich WW, Pyle SL, eds. Radiographic allias of skeletal development of hand wrist. 2nd edn. Stanford CA: Stanford University Press; 1959.
22. Hansman CF. Appearance and fusion of ossification centers in the human's skeleton. Am J Radiol 1962;88:476-82.
23. Hasan M, Naryan DC. The ossification centers of the carpal bones. Indian J Med Res 1963;51;917-20

24. Makay DH. Skelton maturation in the hand: A study of development in East African children. Trans R Soc Trop Med Hyg 1952; 46: 135-50.
25. Rikhasor M, Qurashi AH. Determination of age in children from 1-7 years. Pak J Med 1994;15:38-40.
26. Krogman WM, I Scan My, eds. Skeletal age; early years: the human skeleton of forensic medicine. Springfield: Charles C Thomas publisher; 1986.



AUTHOR AFFILIATION:

Dr. Nizamuddin Memon (*Corresponding Author*)

Professor, Department of Radiology
Liaquat University of Medical & Health Sciences
(LUMHS), Jamshoro, Sindh-Pakistan.
Email: drnizammemon@hotmail.com

Dr. Muhammad Umar Memon

Professor of Forensic Medicine
DOW University, Karachi, Sindh Pakistan.

Dr. Khairunissa Memon

Professor, Department of Gynae Obstetric
Peoples Medical University
Shaheed Benazirabad, Sindh-Pakistan.

Dr. Hirra Junejo

Student
LUMHS, Jamshoro, Sindh-Pakistan.

Dr. Jawairia Memon

Student
DOW University, Karachi, Sindh Pakistan.