

Case Report

Intestinal Obstruction due to Lymphangioma of Mesentery: A Case Report

Nandlal Kella, Prem Kumar Rathi, Shankerlal Rathi, Mohammad Ali Qureshi
and Farman Leghari

ABSTRACT

A case of intestinal obstruction due to lymphangioma of mesentery in a two months old child is presented. Patient presented with signs and symptoms of intestinal obstruction. X-ray showed multiple air fluid levels, while ultrasound was insignificant. Exploration revealed a milky white cyst of mesentery causing complete occlusion at mid ileum. Cyst along with segment of ileum was resected and end-to-end anastomosis made. Post-operative recovery was un-eventful. Histopathological findings were consistent with lymphangioma of mesentery.

KEY WORDS: Lymphangioma of mesentery, Intestinal obstruction, Children.

INTRODUCTION

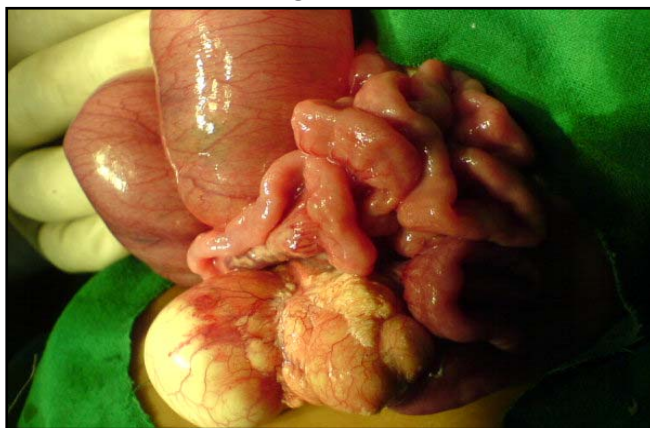Lymphangiomatous malformations are less common than haemangiomas, and those containing chyle are very rare¹. Lymphangiomas are categorized as capillary, cavernous and cystic. Lymphangioma of mesentery is a rare tumor and only a few cases are reported in literature. This malformation has been referred to a variety of names such as mesenteric cyst, cystic lymphangioma of mesentery, chylangioma and chylous cyst². Herein we report a case of chyle containing cyst of mesentery (chylangioma) with intestinal obstruction in a two months old male child.

CASE REPORT

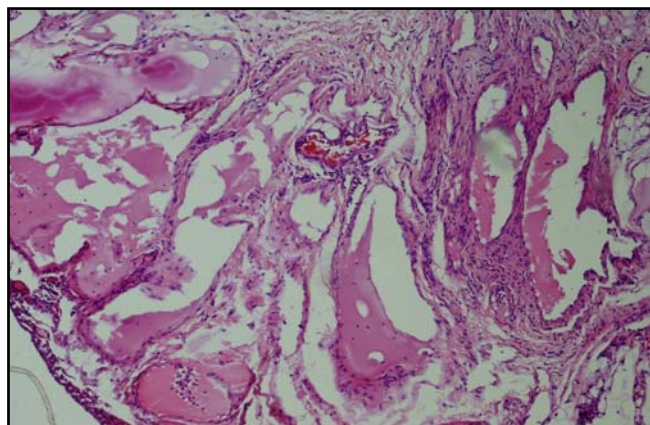
A two months old male child presented with distension of abdomen, bilious vomiting and constipation for three days. On physical examination baby was healthy, weighing 3.6 kg with mild dehydration. Abdomen was moderately distended, tense with visible peristalsis. No lump was palpable. Per-rectal examination was insignificant. X-ray abdomen showed multiple air-fluid levels while ultrasound was insignificant. Complete blood count showed hemoglobin 9.8 gm/dl, total leukocytes count 13000/mm³, while neutrophil count was 70%. Serum electrolytes were slightly deranged and urea was 40mg/dl. Clinical diagnosis of intestinal obstruction was made with suspicion of congenital bands/malrotation. After resuscitation, exploratory laparotomy was performed, which revealed a milky-white cyst approximately 6x5cm in size arising from mesentery of ileum causing complete obstruction at mid ileum (**Figure I**). Proximal intestinal loops were dilated and distal intestine was collapsed. Cyst along with small segment of intestine was resected and end-to-end bowel anastomosis made. Cyst was single and contained approximately 10-15ml milky-white fluid (chyle). Post-operative recovery was un-eventful. Histopathological report showed that cyst

wall was lined by flattened epithelium with multiple lymphatic channels; aggregates of lymphocyte were also seen in the wall of cyst. Above findings were suggestive of cystic lymphangioma/chylangioma of the mesentery (**Figure II**).

**FIGURE I: LYMPHANGIOMA OF SMALL BOWEL
MESENTERY**



**FIGURE II: HISTOPATHOLOGICAL VIEW OF
LYMPHANGIOMA OF MESENTERY**



DISCUSSION

Lymphangiomas are benign overgrowth of lymphatic vessels³. They occur in places where lymphatics are abundant, common sites being axilla and neck. Intra-abdominal lymphangiomas are rare tumours accounting for 1 per 100,000 hospital admissions for adults and 1 per 35000 for pediatric admission⁴. Common site of intra-abdominal lymphangioma is small bowel mesentery, that accounts for 70% for intra-abdominal lymphangioma and 1% of all lymphangioma^{5,6}. They are variable in size and their contents may be serous fluid or chyle. They may be called as chylangioma or chylous cyst when content is chyle. Etiology of mesenteric lymphangioma is unclear. Most acceptable theory suggests that lymphangiomas result from sequestration of lymphatic tissues during embryological development. In adults abdominal trauma, lymphatic obstruction, inflammation, surgery and radiation are considered as factors for sequestration of lymphatic tissues causing lymphangioma⁷. Traditionally lymphangiomas are classified as capillary, cavernous and cystic³. Capillary type is commonly located in skin and composed of small thin-walled lymphatic vessels. Cavernous type is composed of dilated lymphatic vessels and lymphoid stroma and has communication with normal adjacent lymphatics. In small bowel mesentery the spaces may be filled with chyle, hence these are named chylangioma. Cystic lymphangiomas contain lymphatic spaces of variable size and have no communication with normal lymphatic channels; contents may be fascicles of smooth muscles and collagen fibers. However, cystic lymphangioma is not always clearly distinguishable from cavernous variety because cystic variety may also contain cavernous area³. Presentation of intra-abdominal lymphangioma is diverse, ranging from asymptomatic cyst to acute abdomen. Other acute problems are traumatic rupture, intra-abdominal bleeding, volvulus, infection in cyst and intestinal obstruction;⁶ as in our case. Ultrasound is a sensitive diagnostic tool in detecting an intra-abdominal cyst but may not be helpful when intestinal loops are distended with gas; as in this case. A CT scan is more reliable for diagnosis;⁸ it is indicated when there is suspicion of cyst on clinical examination or ultrasonography. Treatment of choice of

mesenteric lymphangiomas is total excision but it may not always be possible. With regard to surgical management, they are categorized into four types, depending upon size and extent of cyst. (1) pedunculated; they are more prone for torsion and volvulus, and are easily resectable, (2) sessile; they are less mobile and may alter bowel blood supply and require bowel resection, (3) retroperitoneal extension; they may involve the vital structure and complete removal may not be possible (4) multicentric; in case of extensive involvement prognosis is not good⁹.

CONCLUSION

Intra abdominal lymphangioma may be asymptomatic and discovered incidentally or may present with acute abdomen. Surgical intervention is required in all sorts of presentations to prevent fatal complications. Though rare, intra-abdominal lymphangioma may be kept in mind when dealing with acute abdomen.

REFERENCES

1. Field ES. Cavernous chylangioma of jejunal mesentery. *Br Med J.* 1971; 3(5752):27-8.
2. Dalaker K. Chylous cyst of mesentery of the colon Report of a case. *Acta Chir Scand* 1997; 145 (3):7-8.
3. Orinase R , Vikram S, Prabhati P. Lymphangioma of tonsil a rare case study. *Indian J Otolaryngo Head /Neck Surg.* 2005; 57(4):332-4.
4. Algahtani A, Nguyen LT, Flageole H, Shaw K, Laberge JM. Twenty-five years experience with lymphangioma in children. *J Pediatr Surg* 1999; 341:1164-8.
5. Rieker R, Quenteneier A, Weiss C, Kretzschmar U, Amman K, Mechtersheimer G, et al. Cystic lymphangioma of small bowel mesentery. *Pathol Oncol Research.* 2000; 6(2):146-8.
6. Chen CW, Hsu SD, Lin CH, Cheng MF, Yu JC. Cystic lymphangioma of jejunal mesentery in an adult: A case report. *World J Gastroenterol* 2005; 11(32):5084-6.
7. Soni JP, Gupta BD, Singh MP, Soni M. Lymphomatous mesenteric cyst. *Indian Pediatr* 1999; 36:522-4.
8. Prabhakaran K, Patnakar JZ, Loh DLSK, Ali AF. Cystic lymphangioma of the mesentery causing

intestinal obstruction. Singapore Med J 2007; 48 (10):265-7

9. Iwabuchi A, Otoka M, Okumaya A. Disseminated

intra-abdominal cystic lymphangioma with severe intestinal bleeding: A case report. J Clin Gastroenterol 1997; 25:383-6.



AUTHOR AFFILIATION:

Dr. Nandlal Kella (*Corresponding Author*)

Assistant Professor
Department of Pediatric Surgery
Liaquat University of Medical and Health Sciences
(LUMHS), Jamshoro, Sindh-Pakistan.
E-Mail nckella@yahoo.com

Dr. Prem Kumar Rathi

Assistant Professor
Department of General Surgery
LUMHS, Jamshoro, Sindh-Pakistan.

Dr. Shankerlal Rathi

Professor of Histopathology
Department of Pathology
LUMHS, Jamshoro, Sindh-Pakistan.

Dr. Mohammad Ali Qureshi

Resident Pediatric Surgery
LUMHS, Jamshoro, Sindh-Pakistan.

Dr. Farman Leghari

Resident Pediatric Surgery
LUMHS, Jamshoro, Sindh-Pakistan.